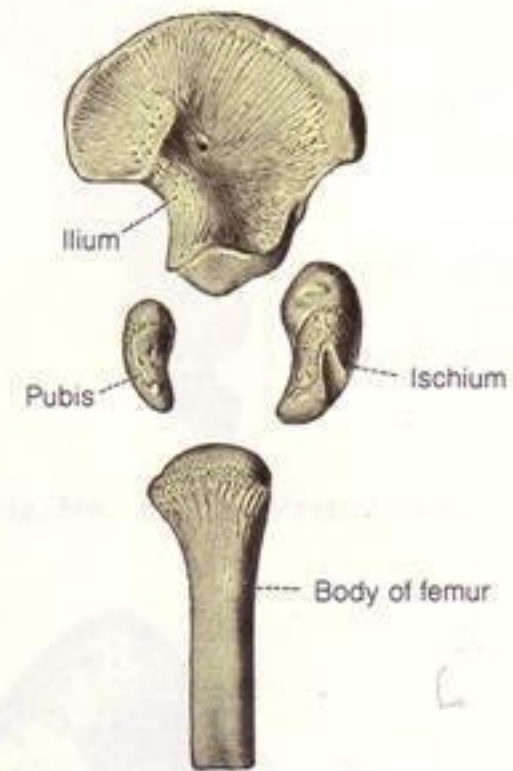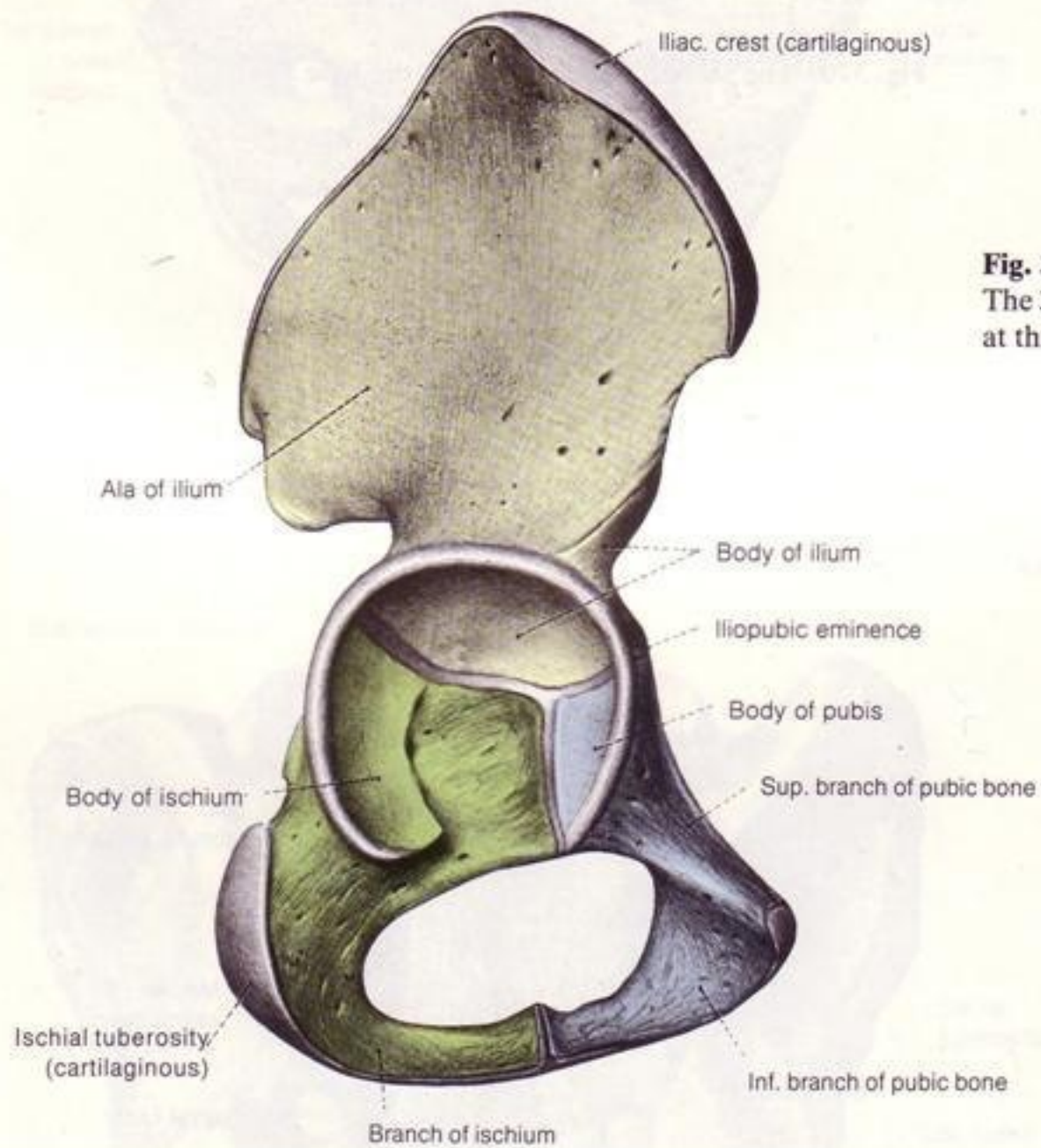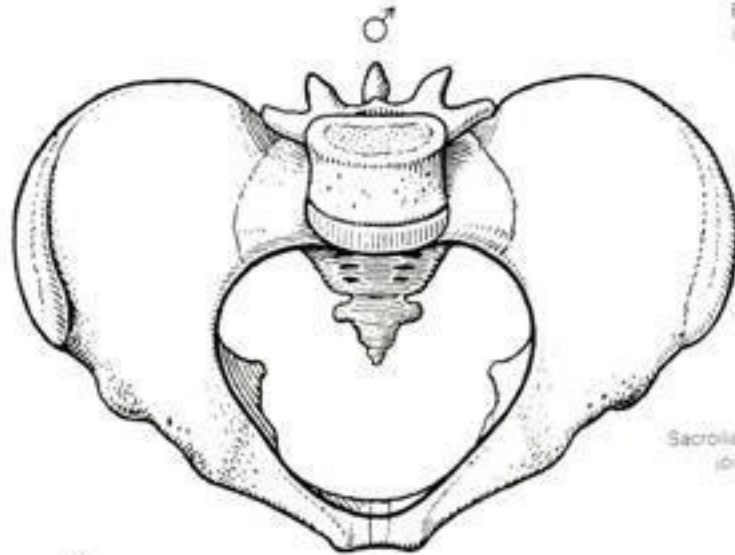
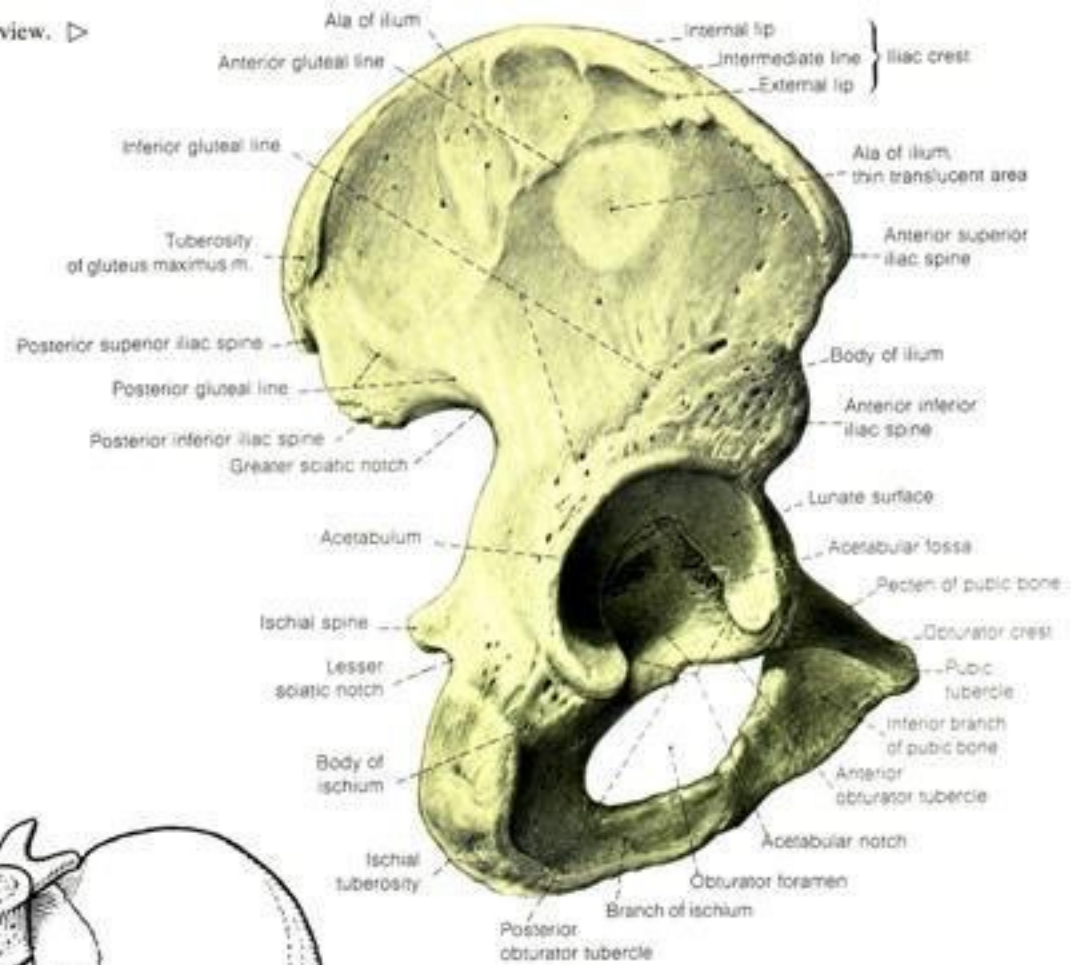
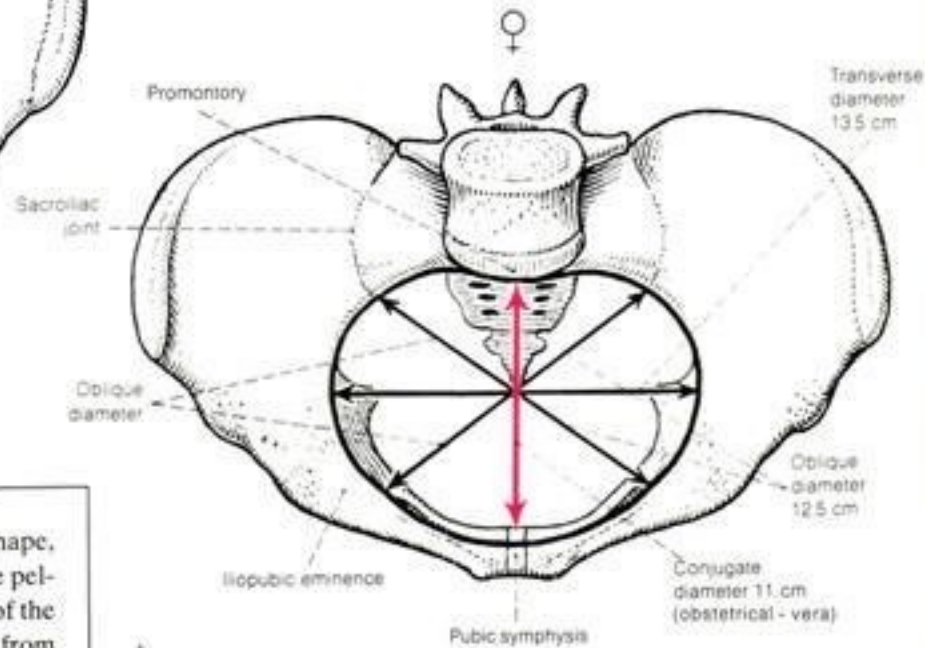


Fig. 373b. Right hip bone and proximal part of the femur at birth. The 3 parts of the hip bone (ischium, ilium, and pubis) are not united at this stage, and the head and neck of the femur are cartilaginous.

Fig. 362. Right hip bone. Lateral view. ▷



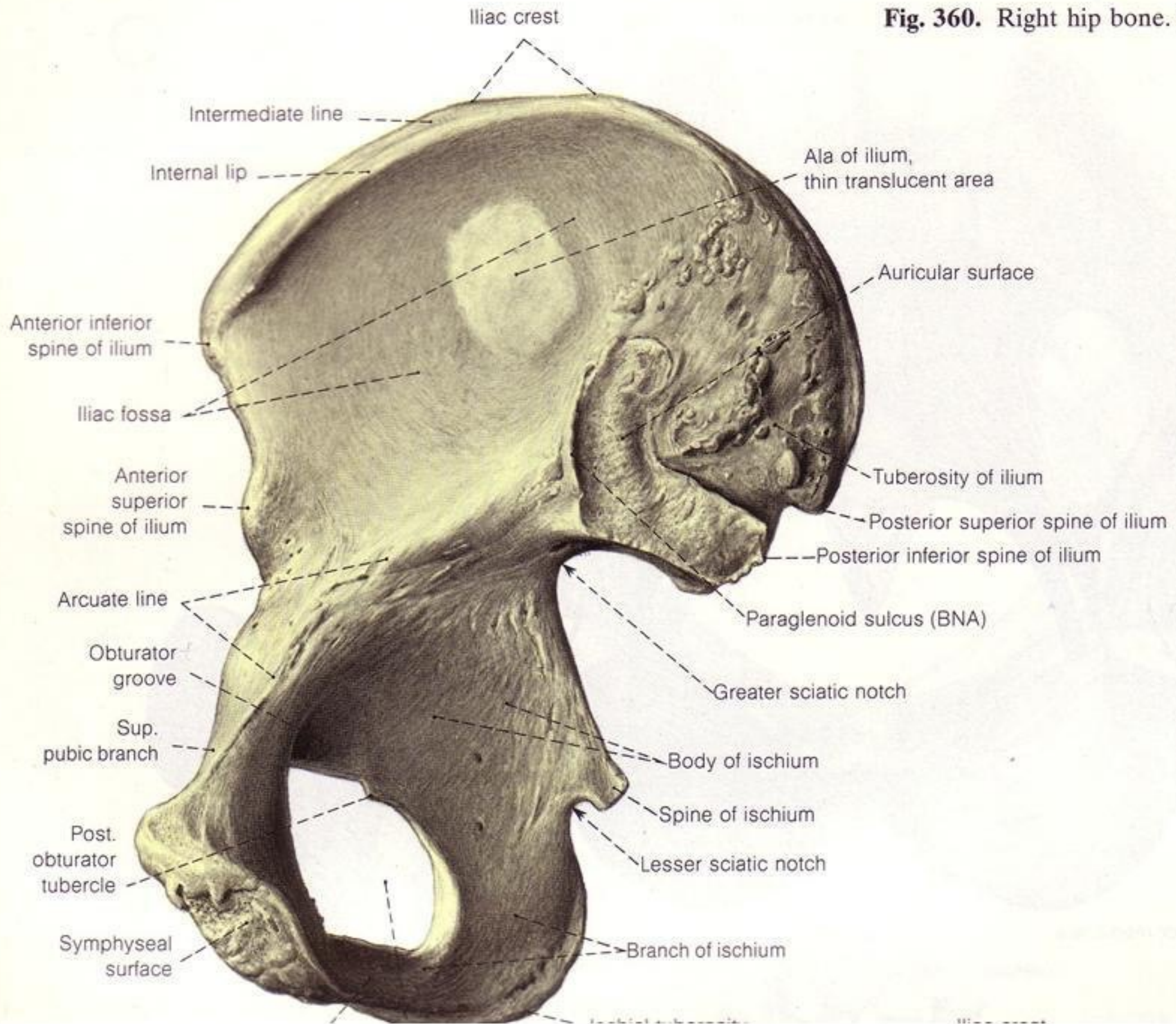
△ Fig. 363. Male pelvis: Heart-shaped pelvic aperture; true pelvis becomes narrower toward the outlet, hence funnel-shaped, subpubic angle.

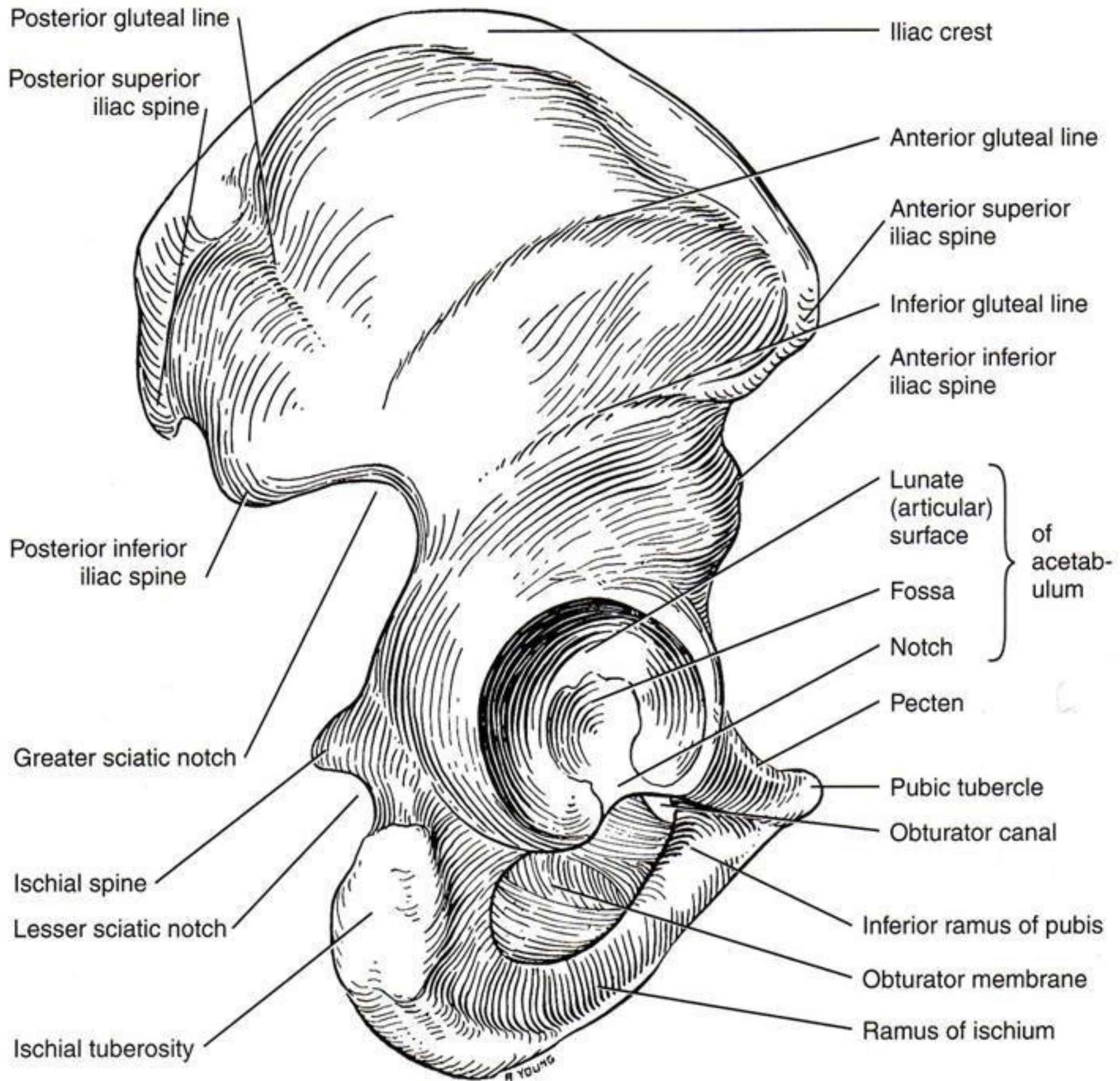


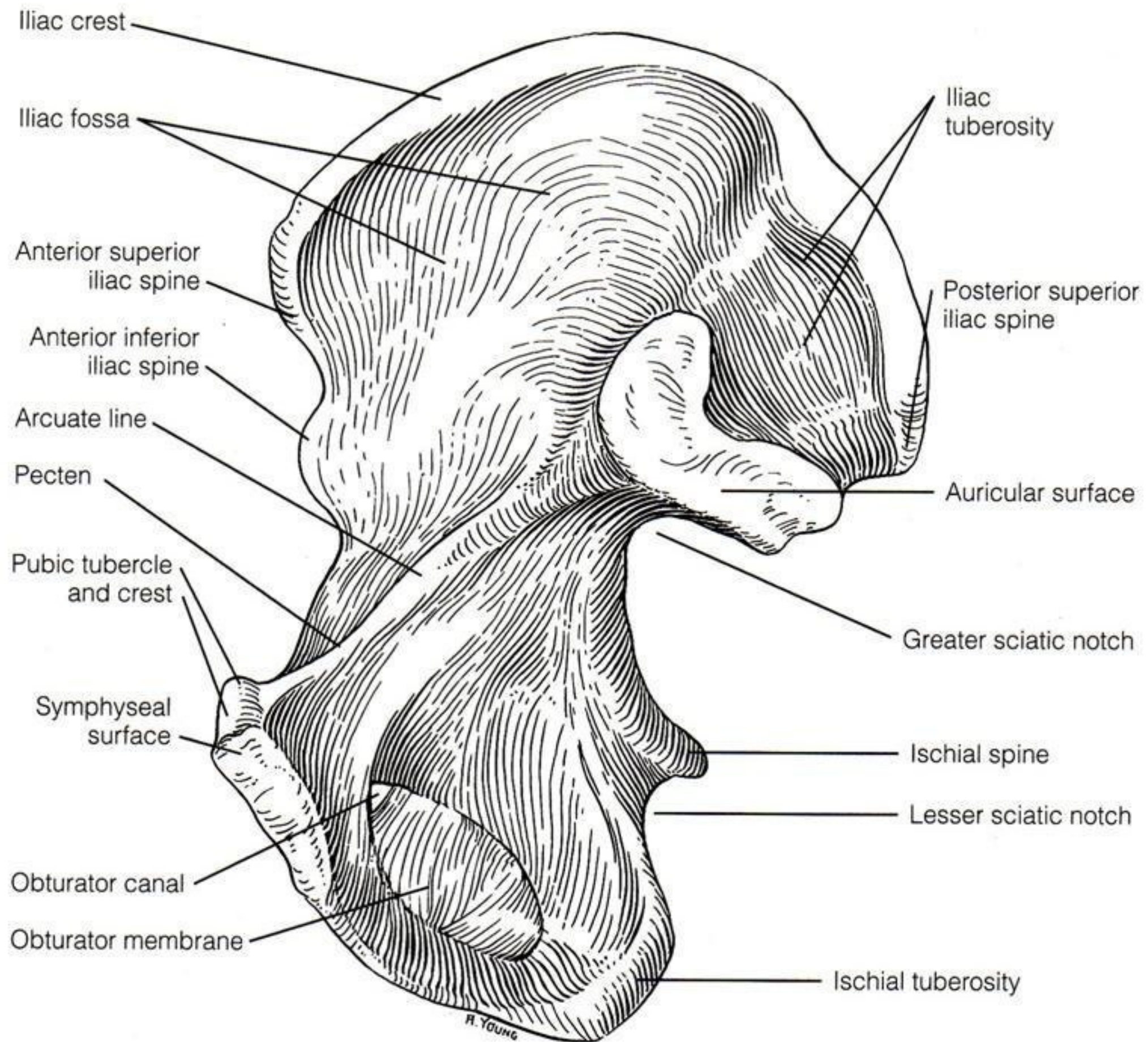
△ Fig. 364. Female pelvis: Slanting oval of the pelvic aperture; cylindrical true pelvis not narrowed toward outlet, subpubic arch.

NOTE: The sex differences, especially in the shape, size, and diameter of the superior aperture of the pelvic apertures, also as to the sacrum and position of the iliac fossa. The left oblique diameter I (12.5 cm) from the left iliopubic eminence to the right sacroiliac joint; the right oblique diameter II (12.5 cm) from the right iliopubic eminence to the left sacroiliac joint; conjugate (11 cm) from the promontory to the most prominent part of the posterior aspect of the symphysis of the pubic bone (red arrow).

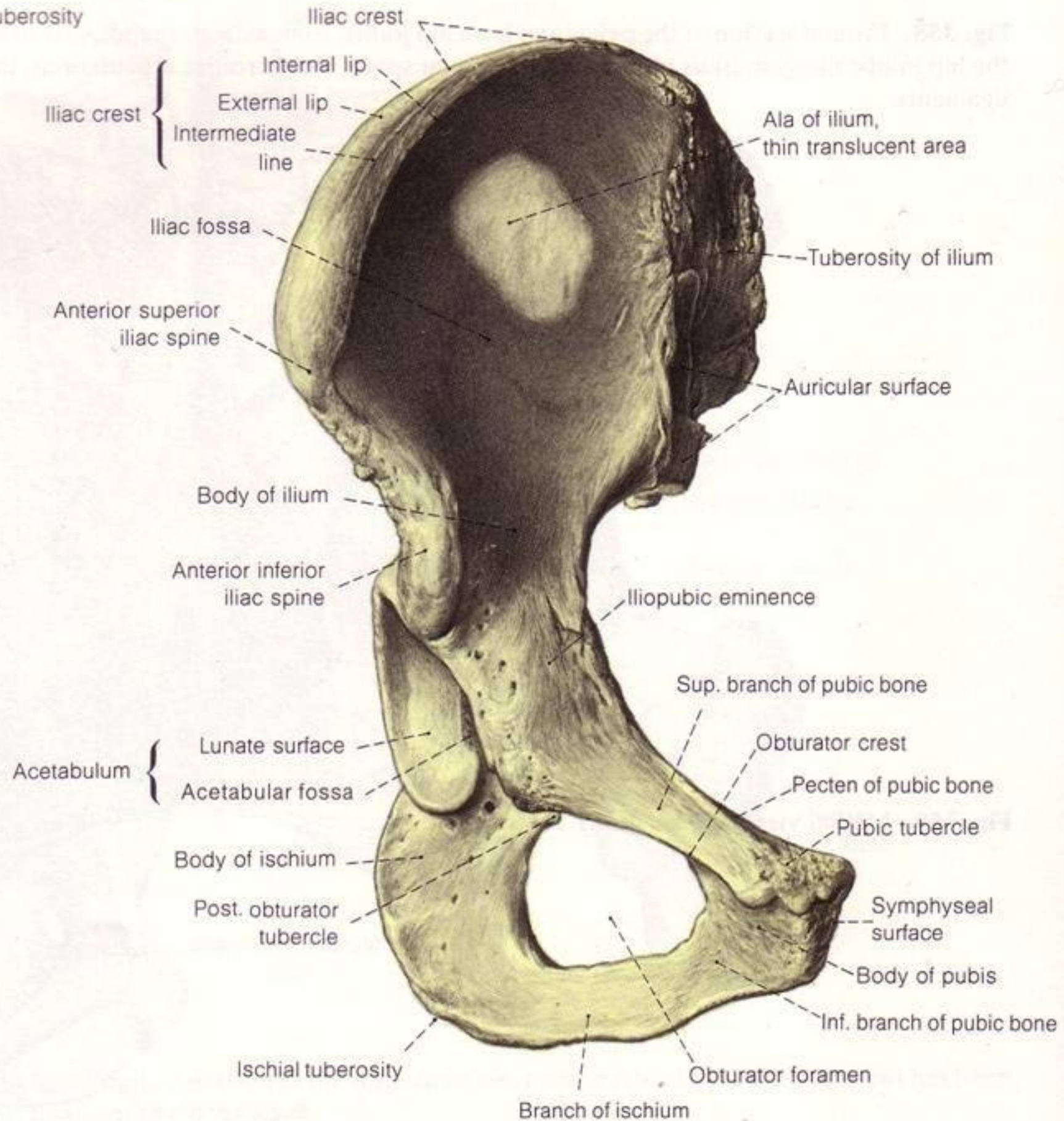
Fig. 360. Right hip bone. Medial view.







tuberosity



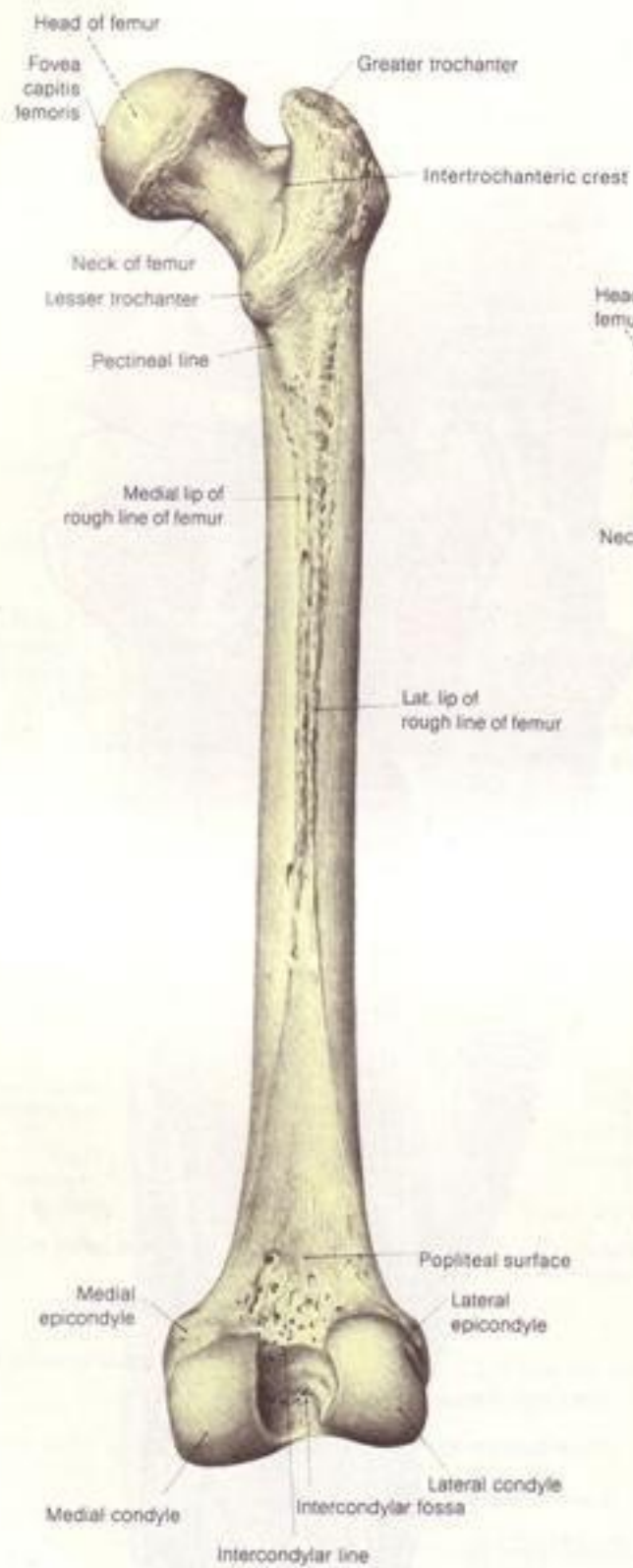


Fig. 422.

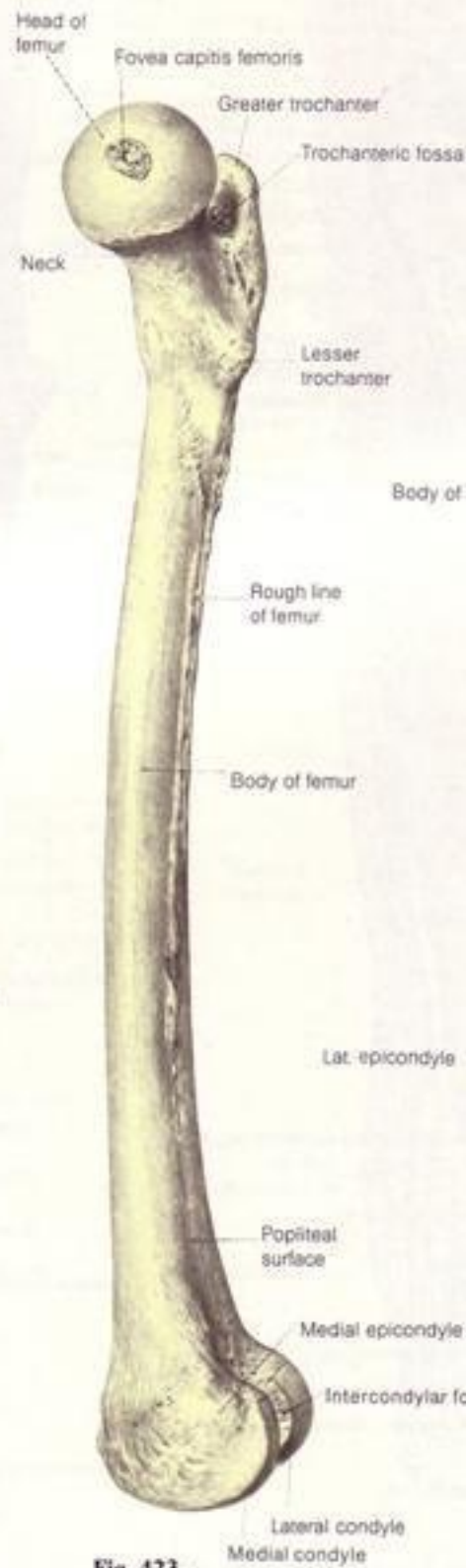


Fig. 423.

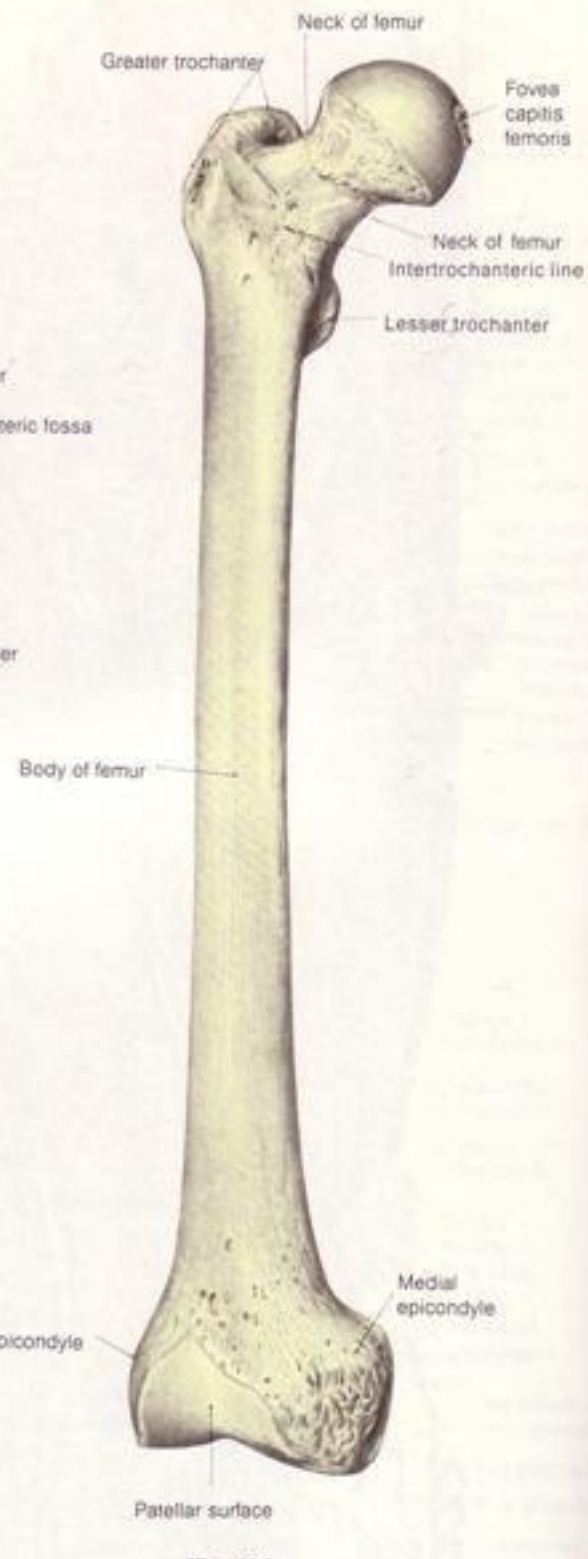
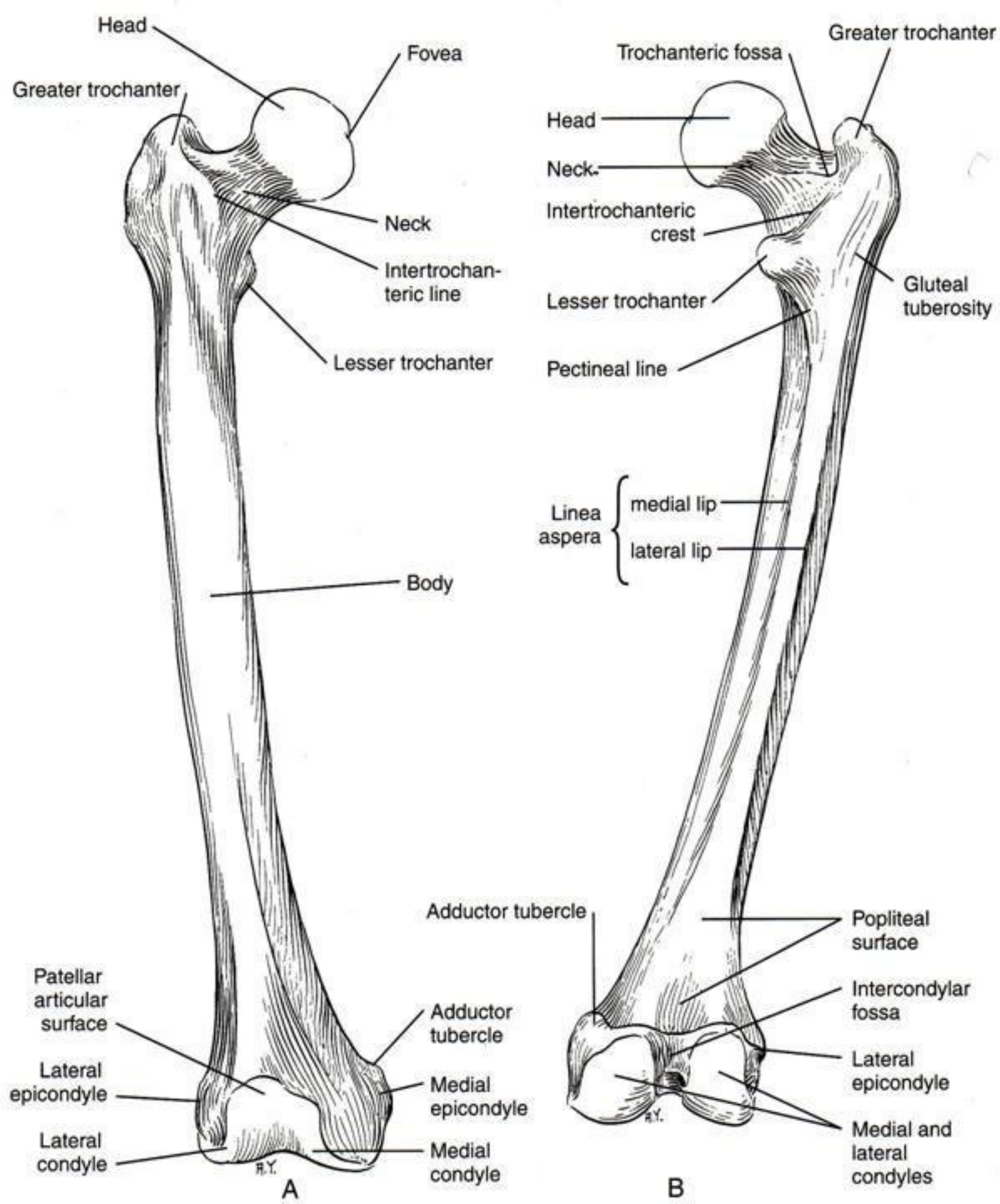


Fig. 424.



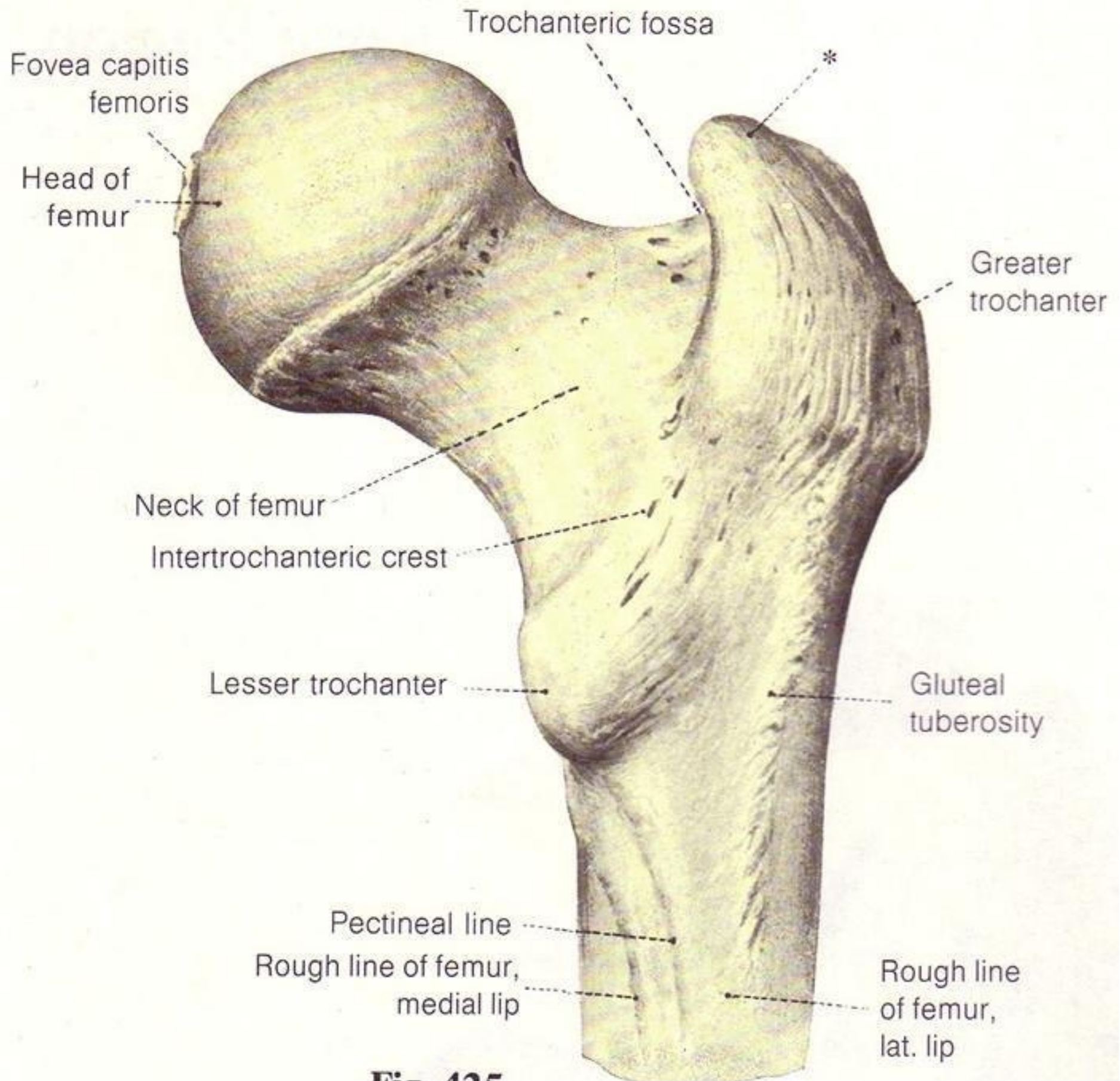
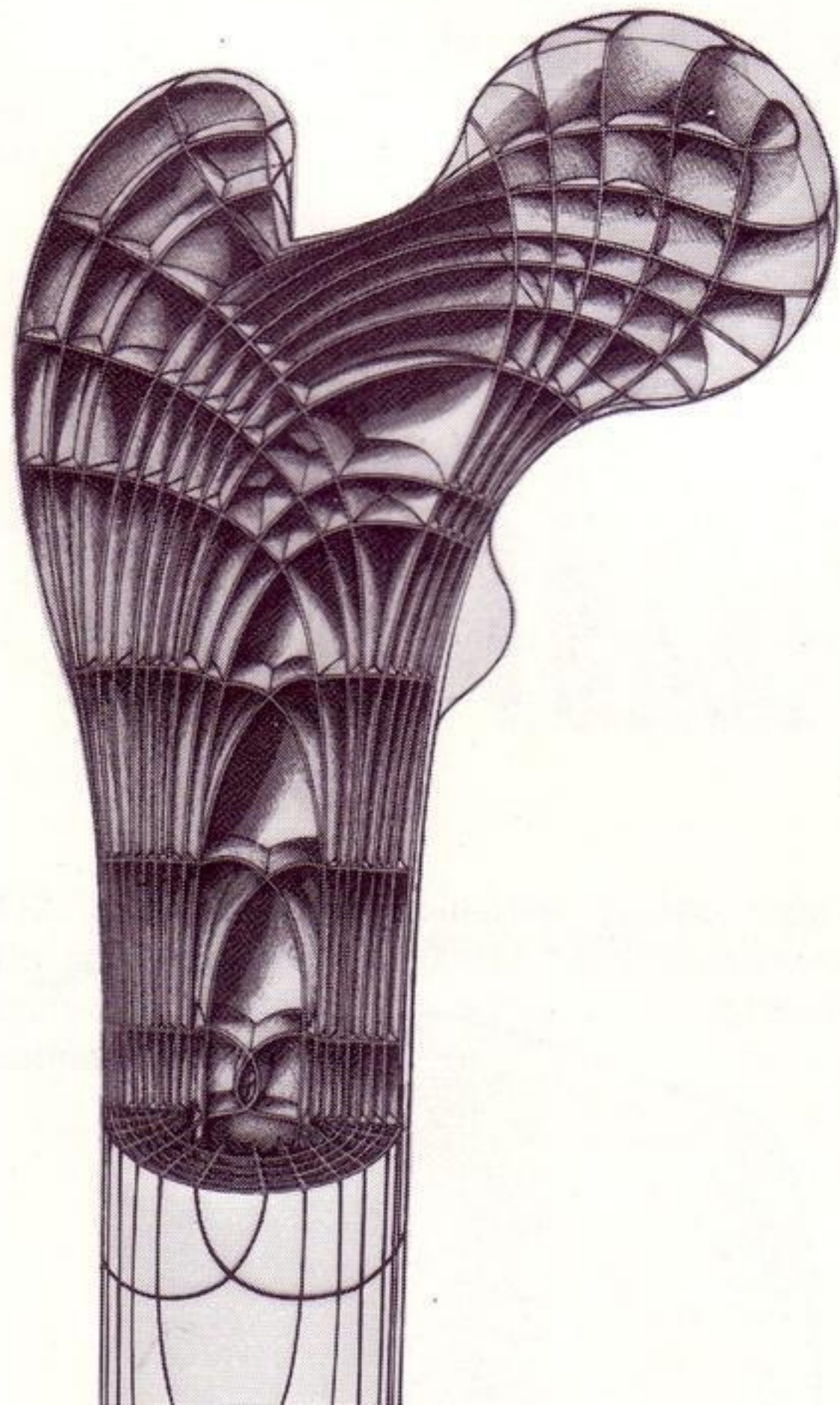
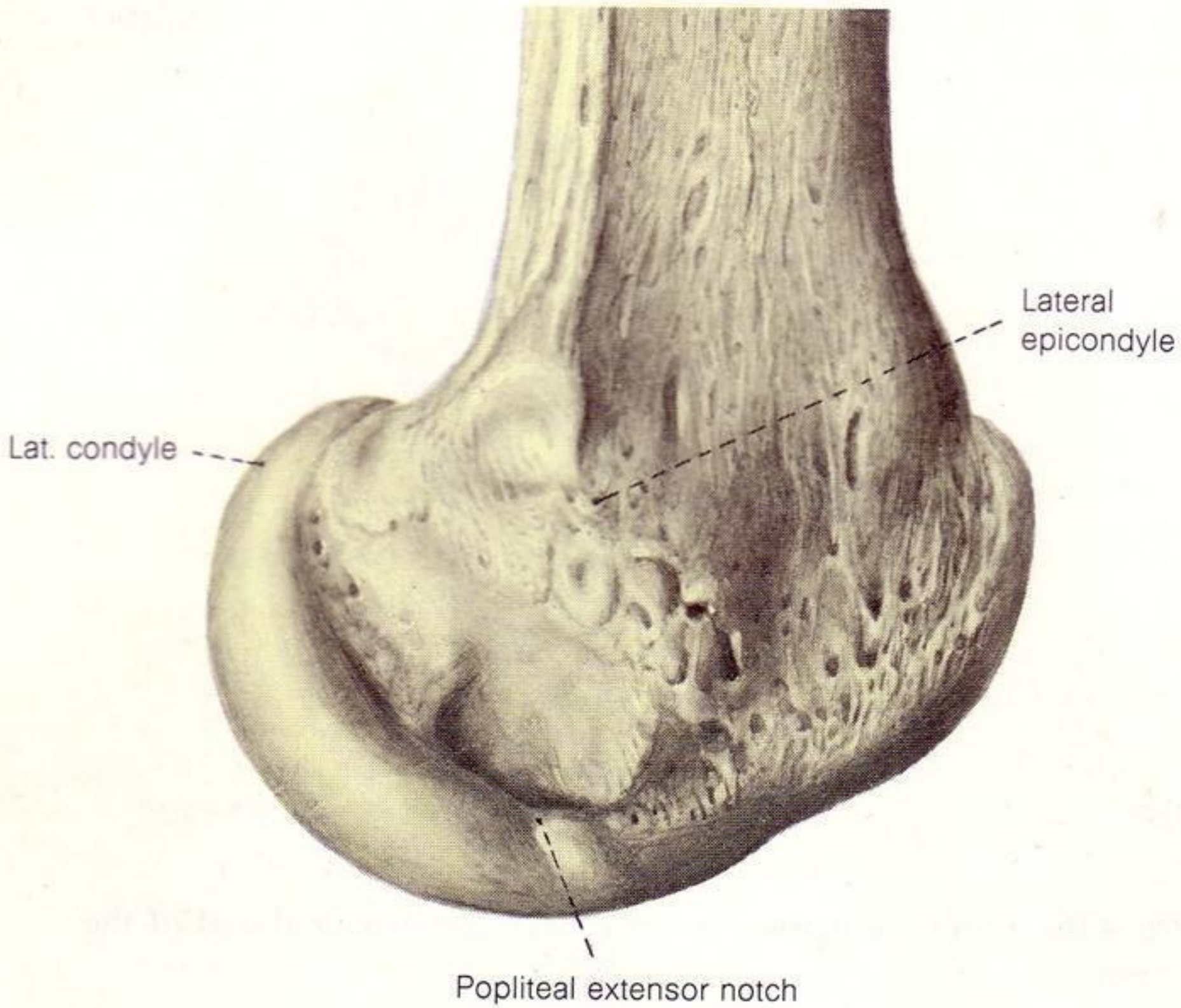


Fig. 105






Lat. condyle

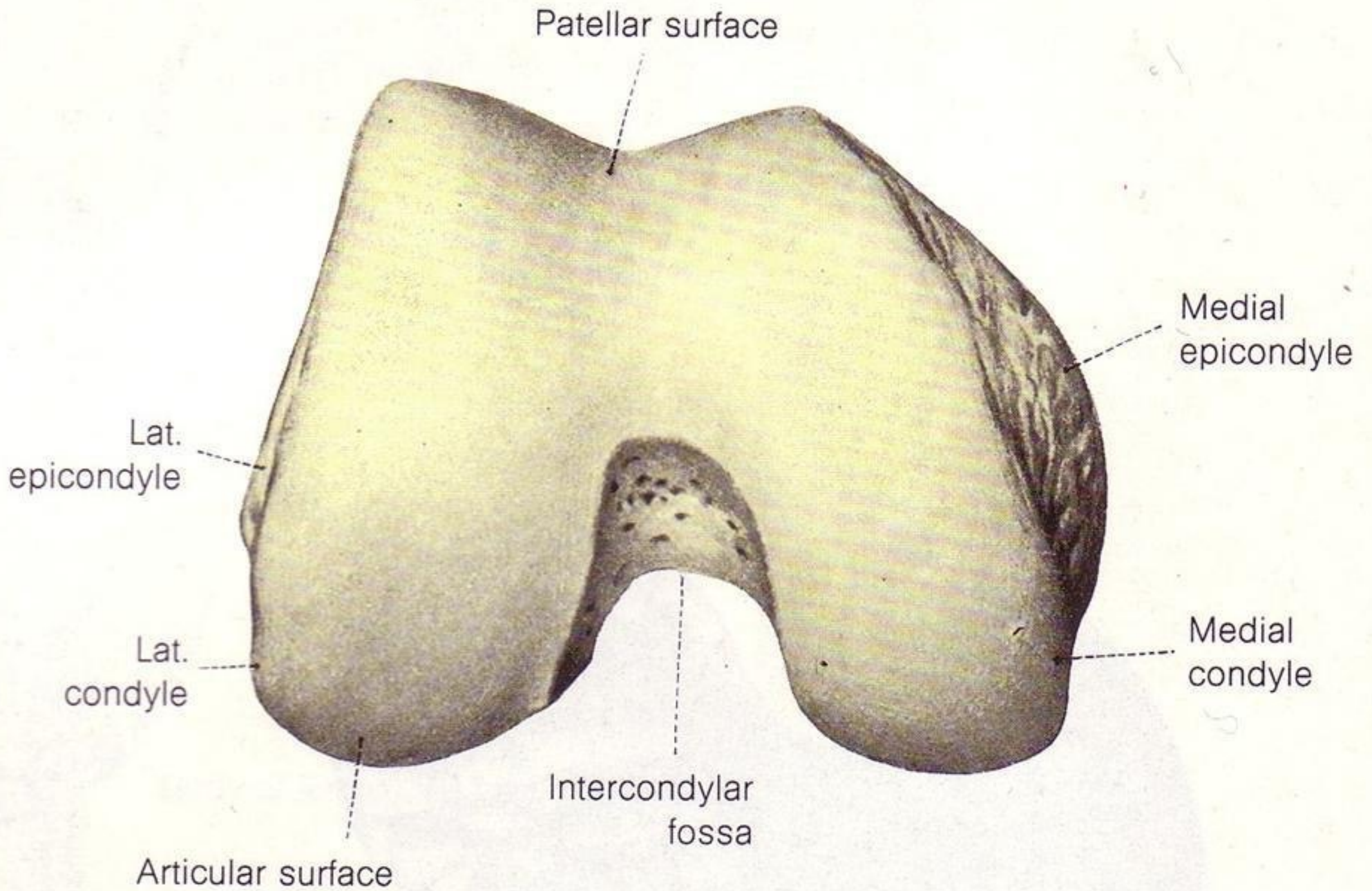
Lateral epicondyle

Popliteal extensor notch

Base of patella

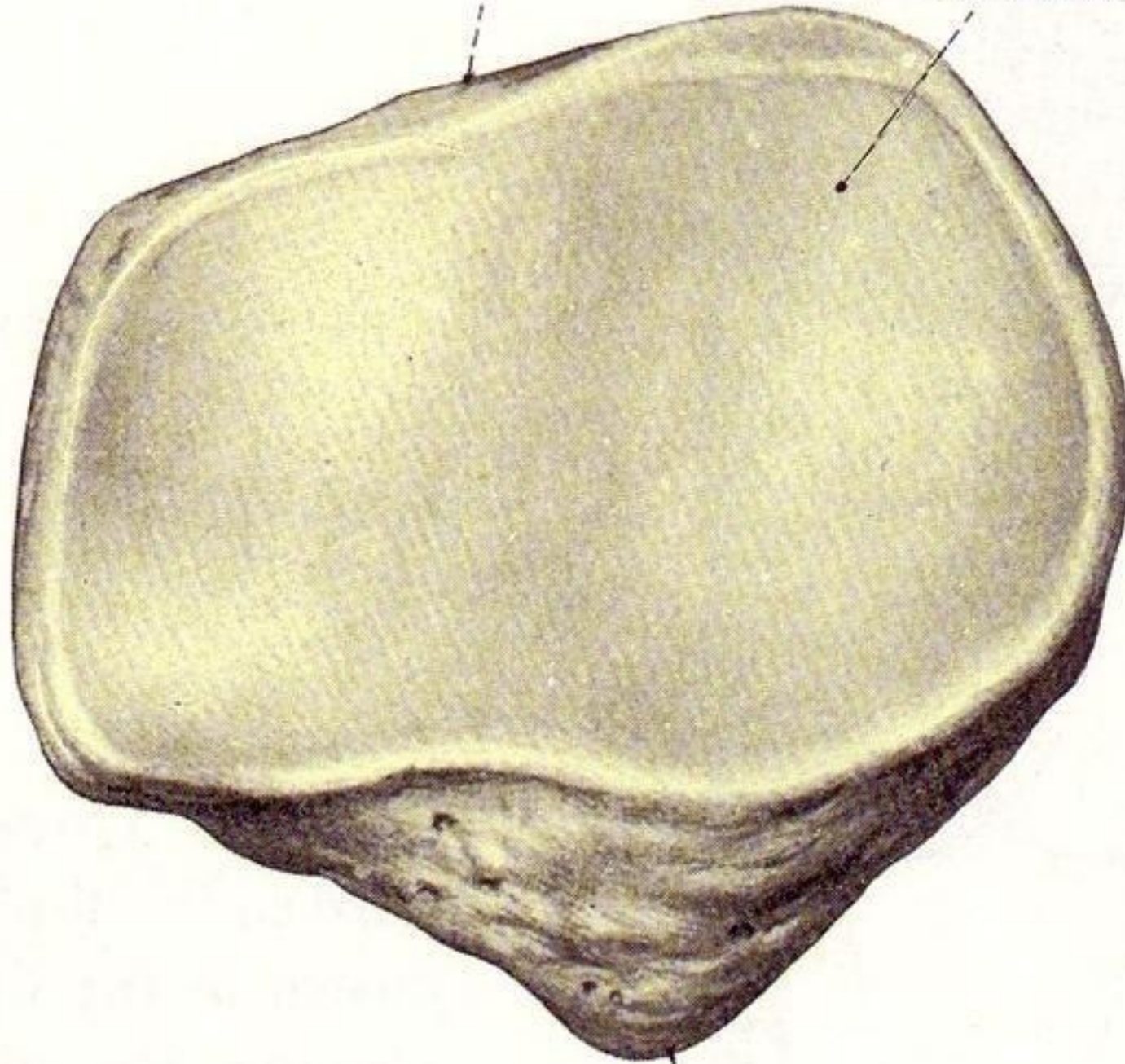


Apex of patella



Base of patella

Articular surface



Apex of patella

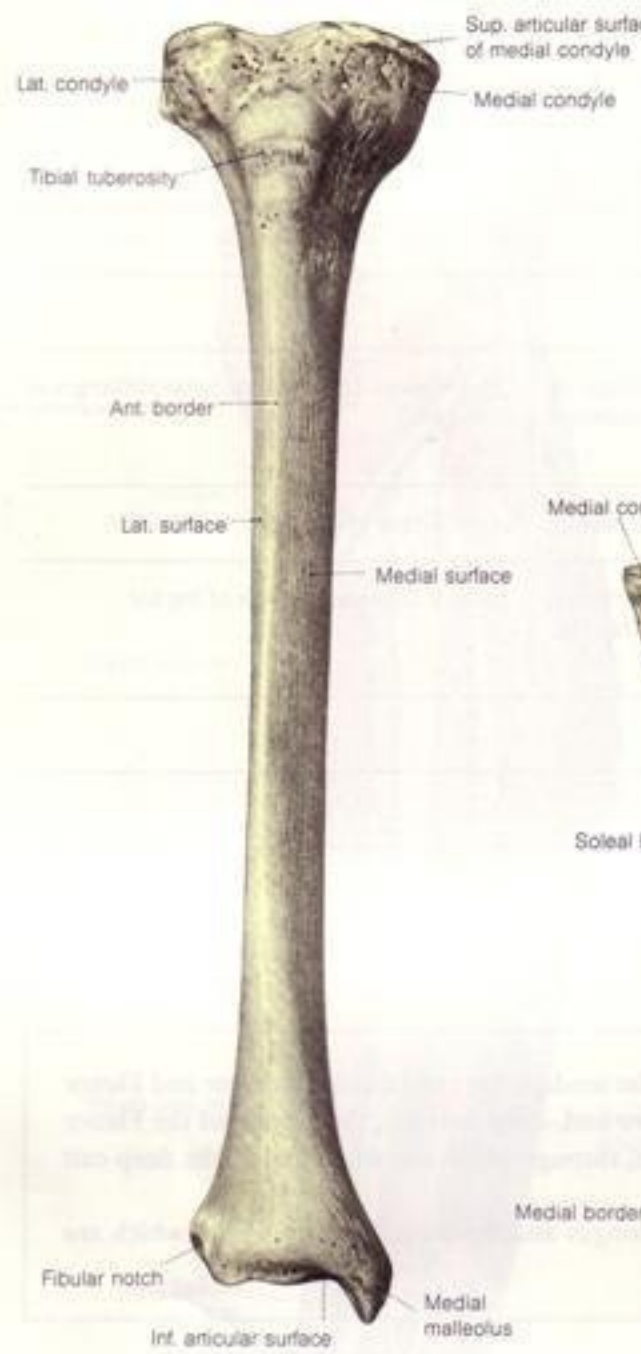


Fig. 477.

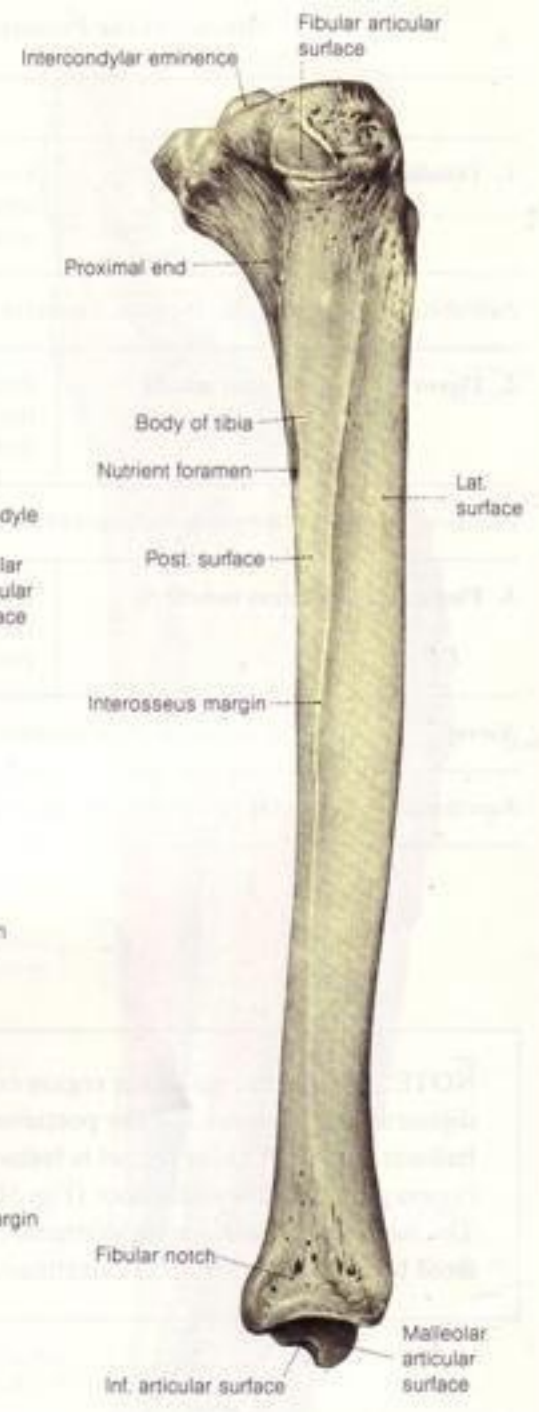
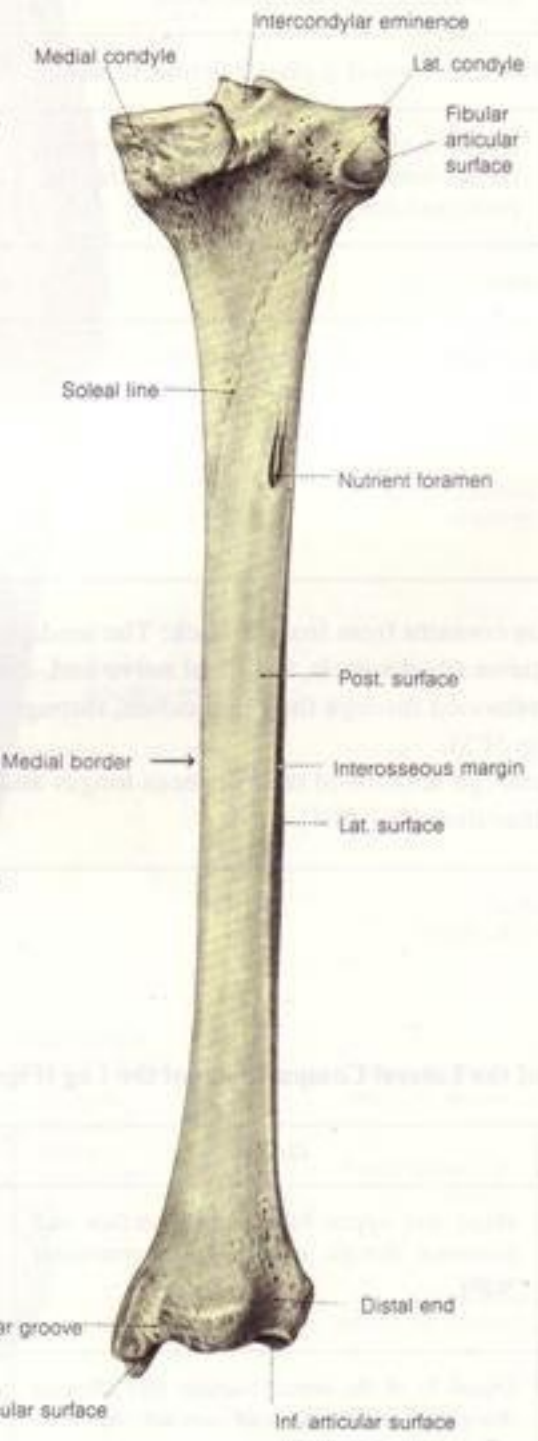
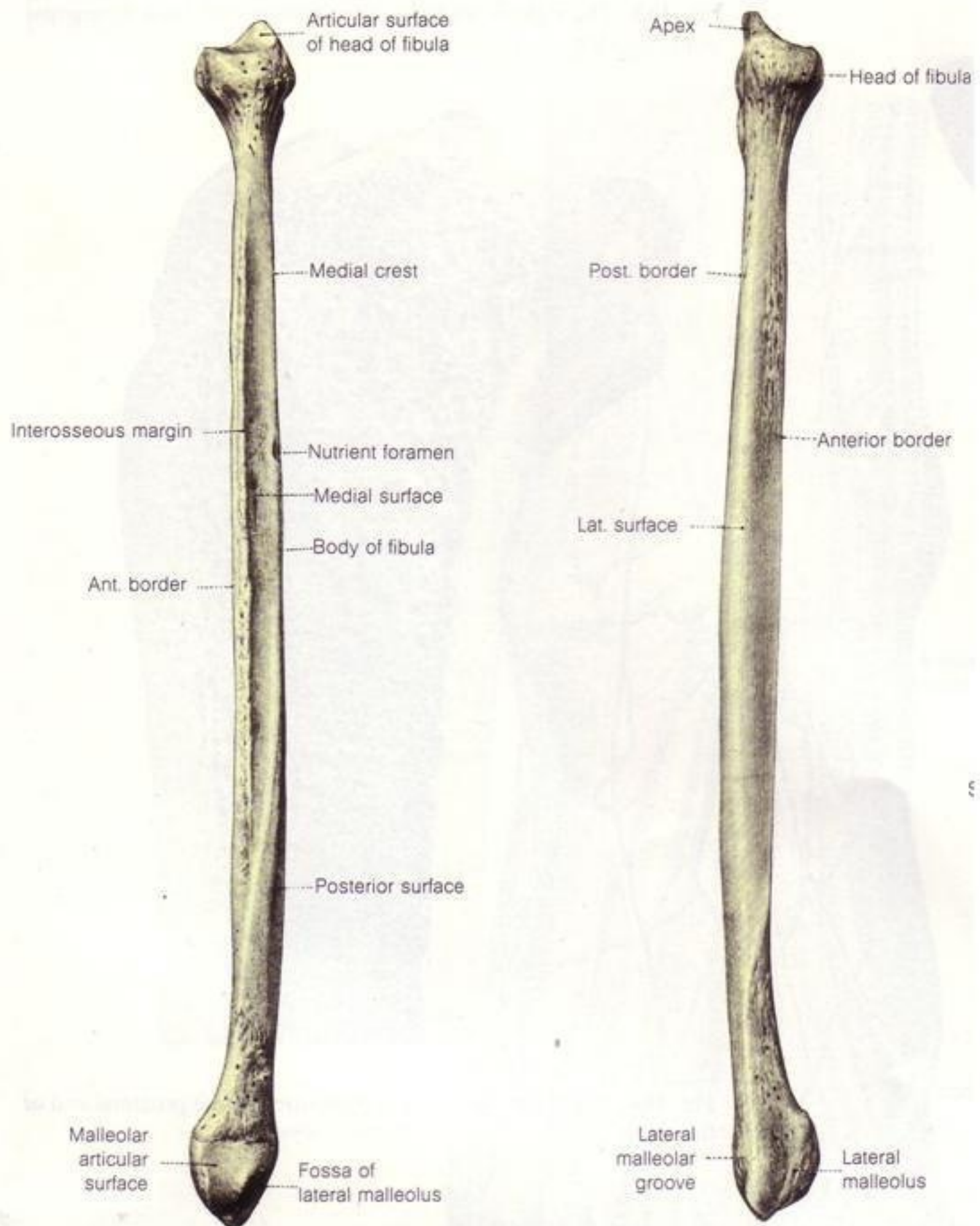
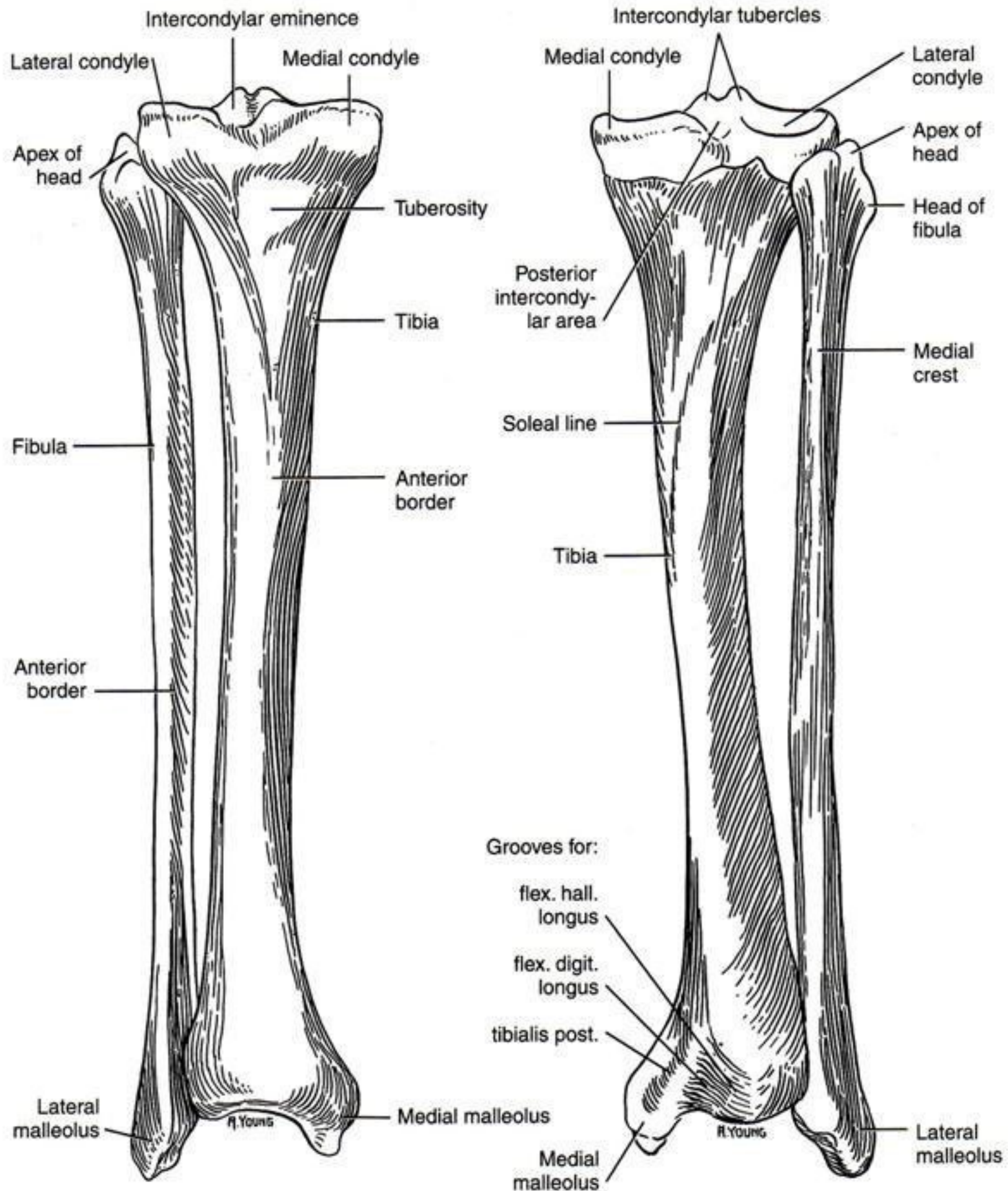


Fig. 479.





Head of fibula

Tuberosity of tibia

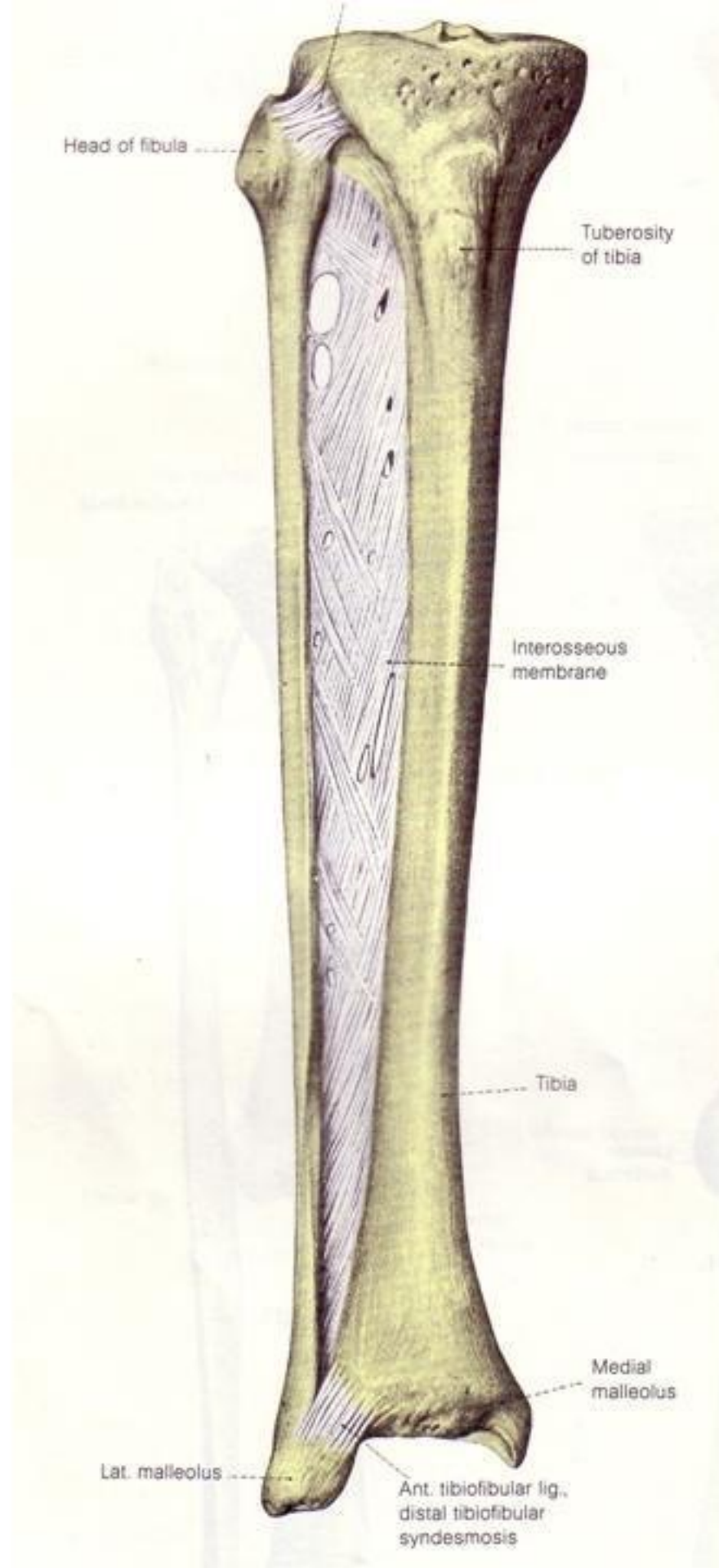
Interosseous membrane

Tibia

Medial malleolus

Lat. malleolus

Ant. tibiofibular lig.,
distal tibiofibular
syndesmosis




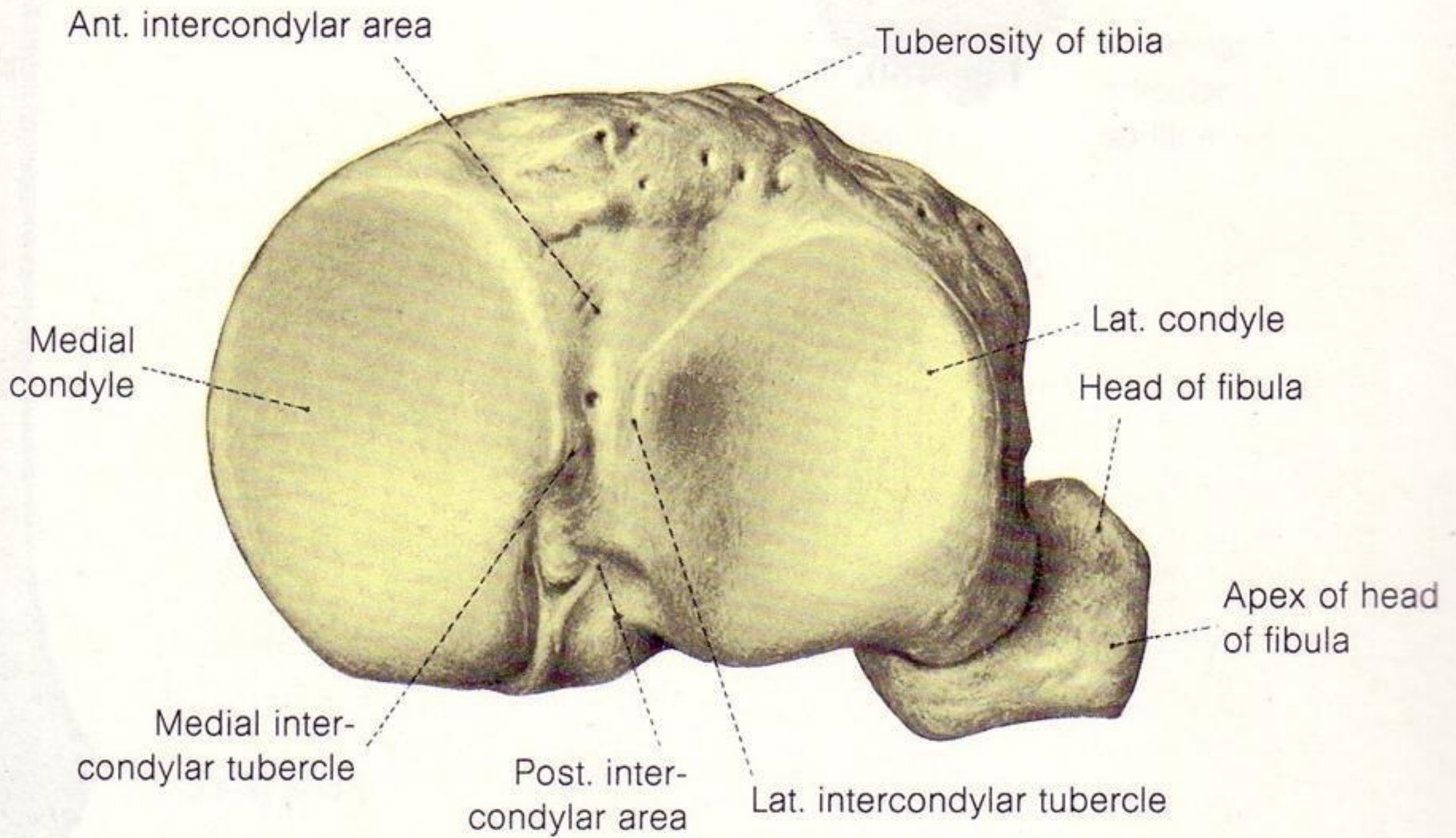
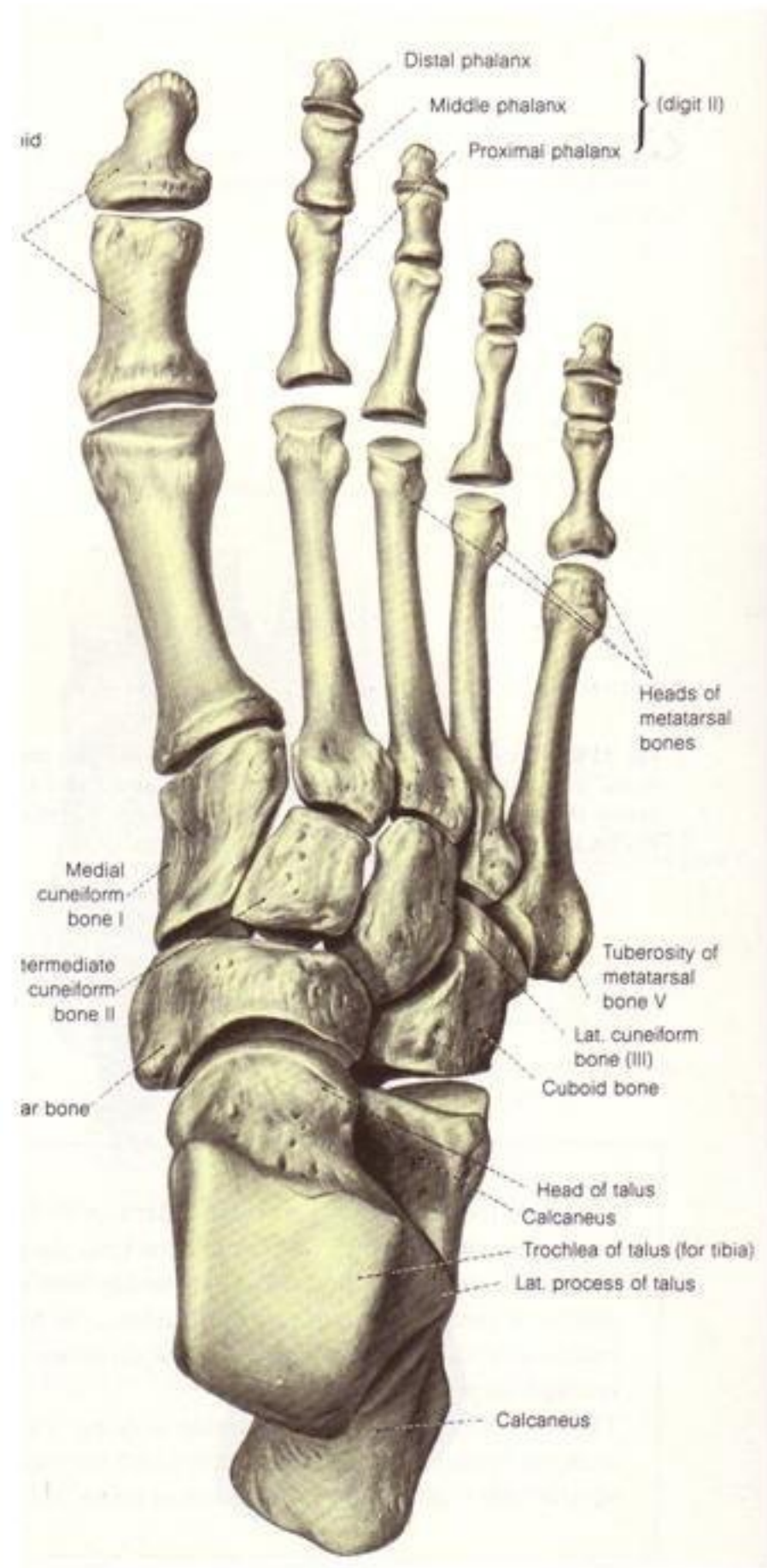
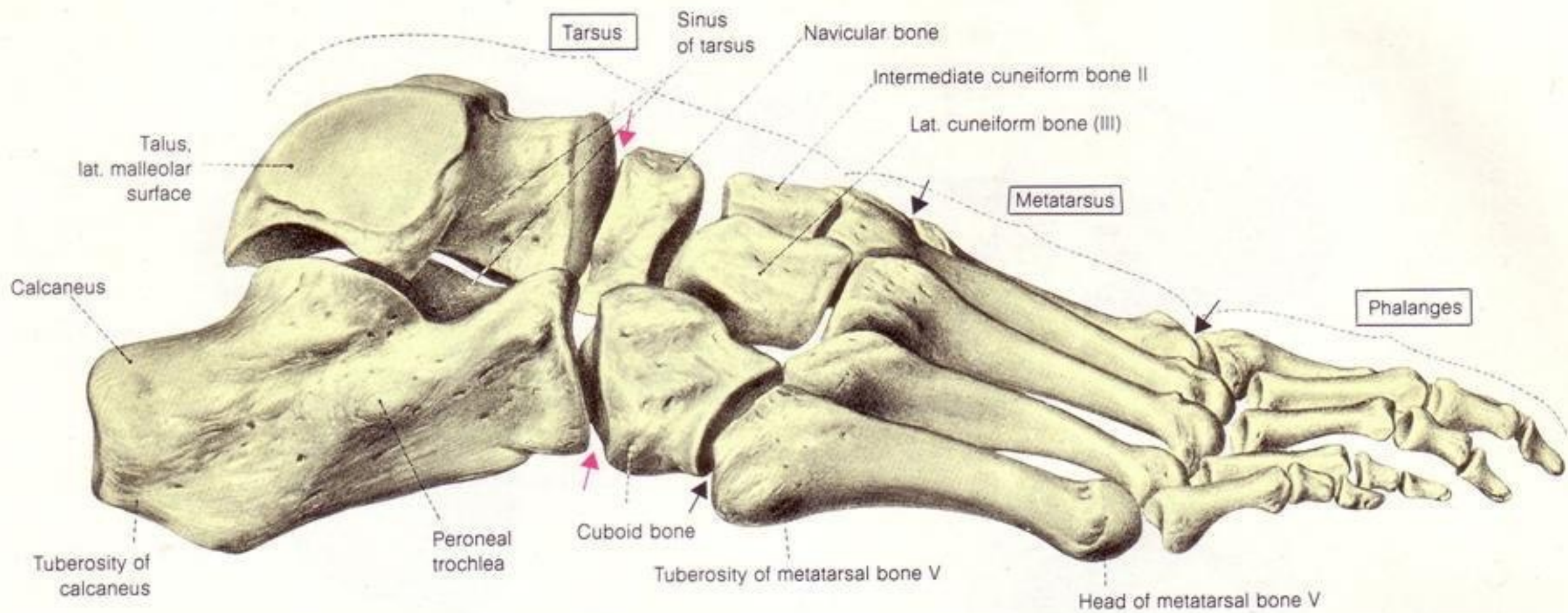


Fig. 482.





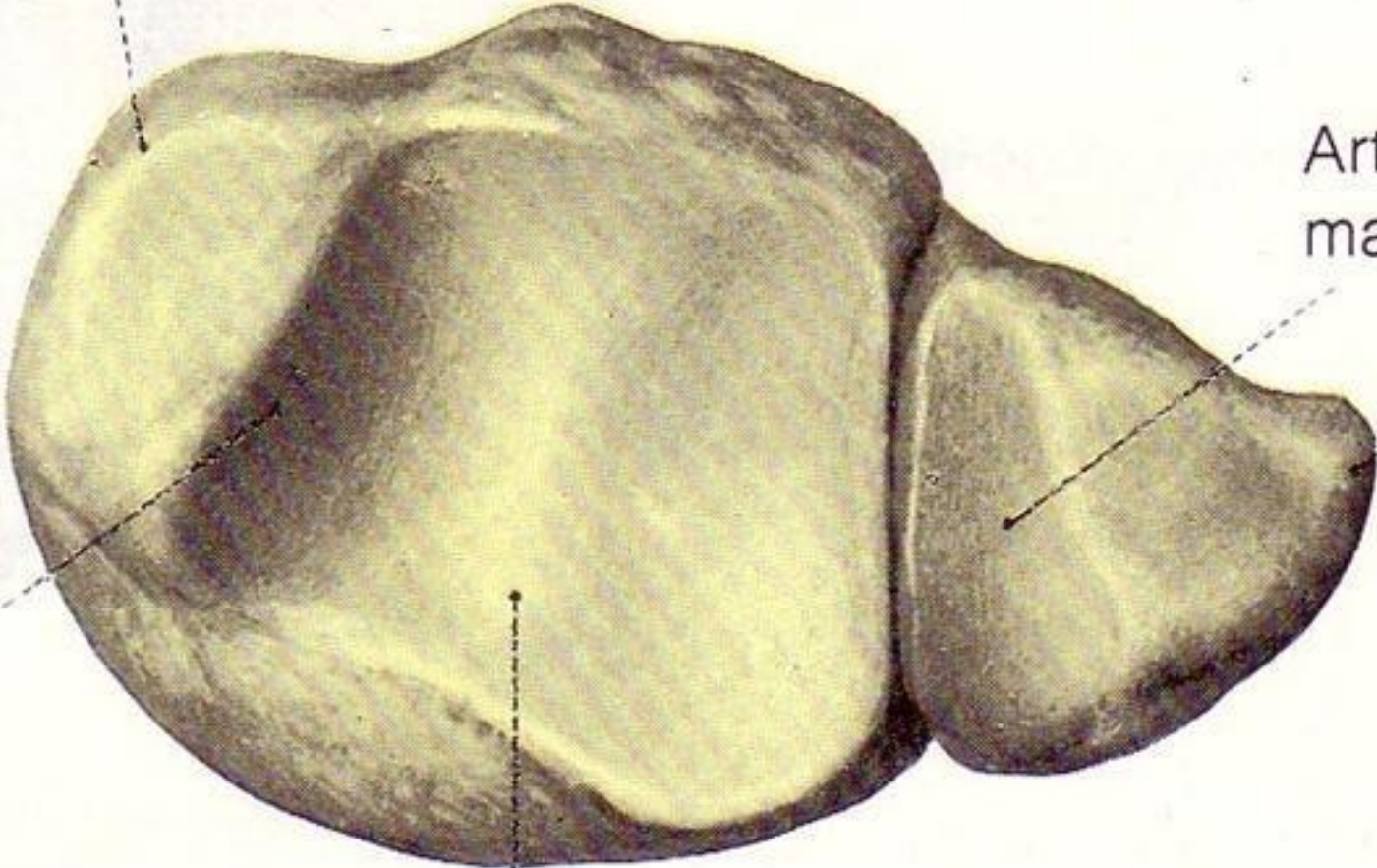


Medial malleolus

Articular surface,
malleolus

Lat.
malleolus

Medial
malleolar
articular
surface



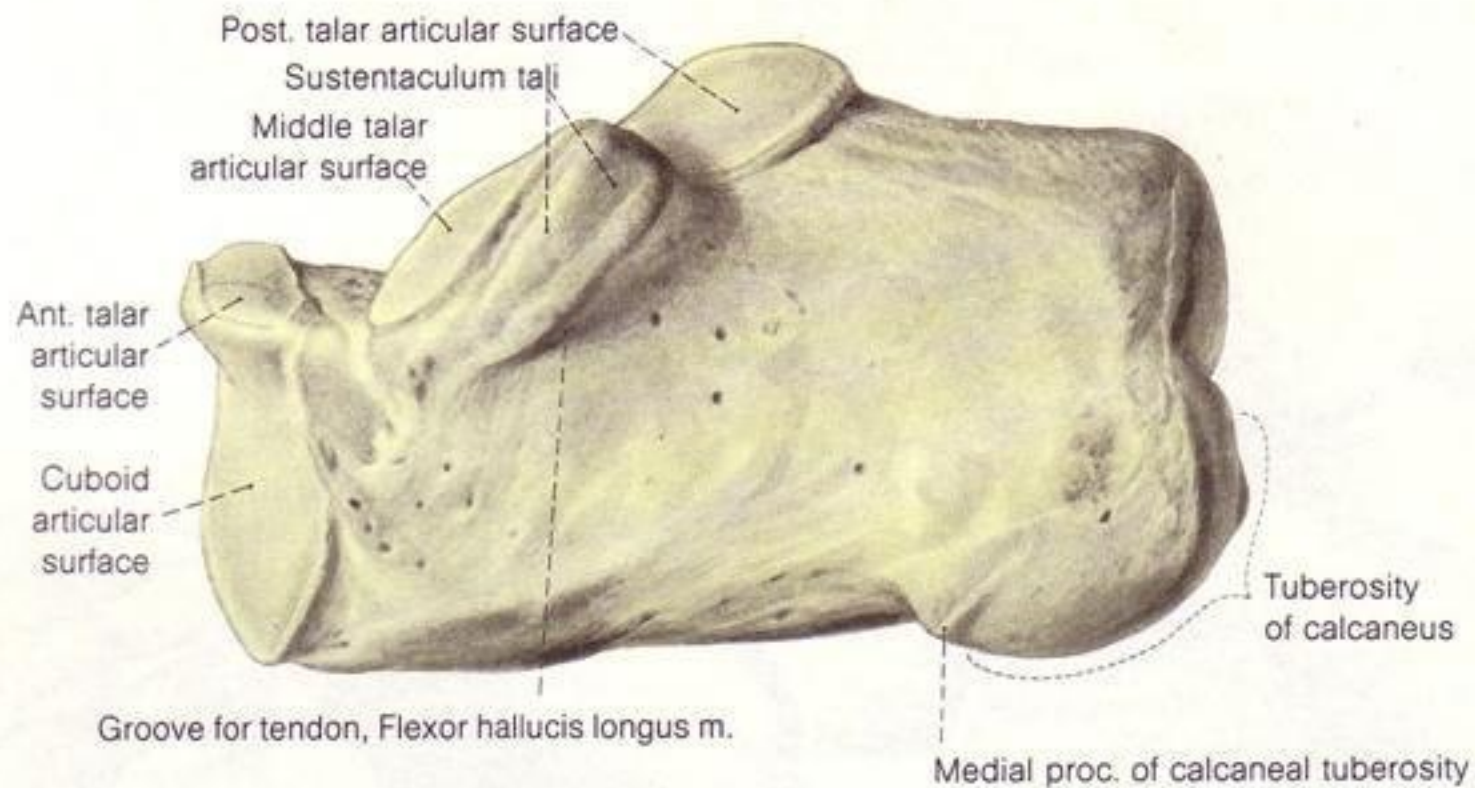
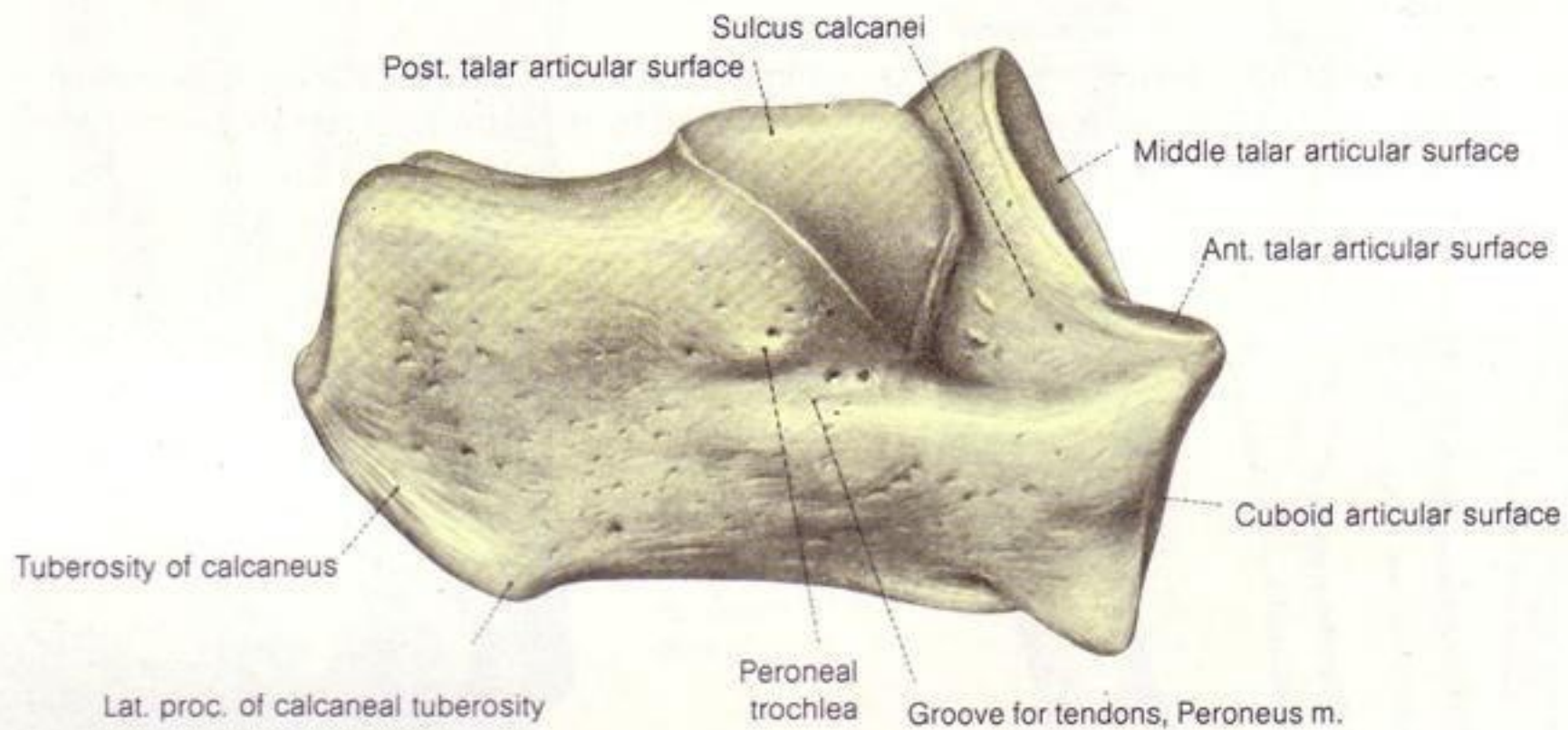
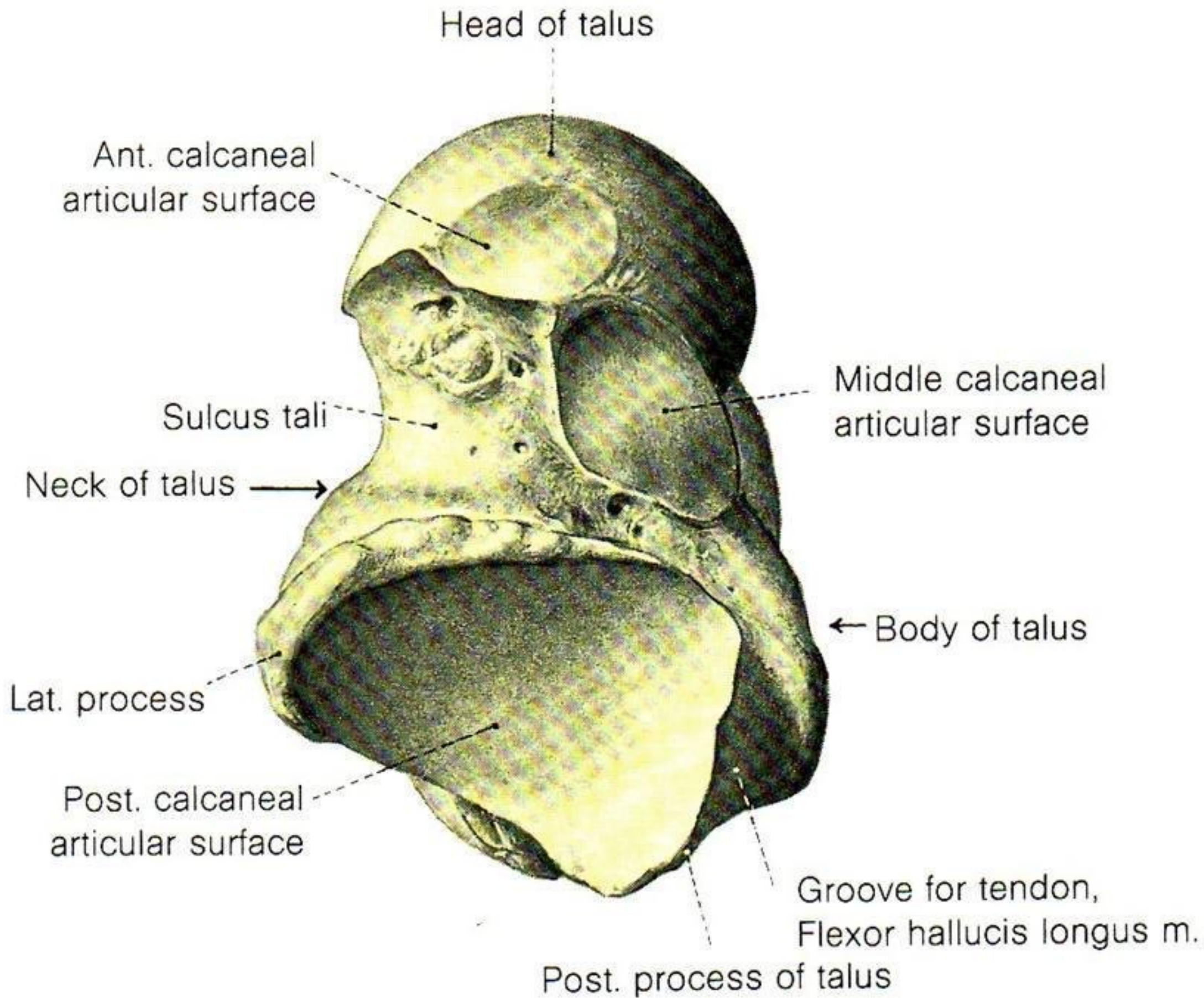
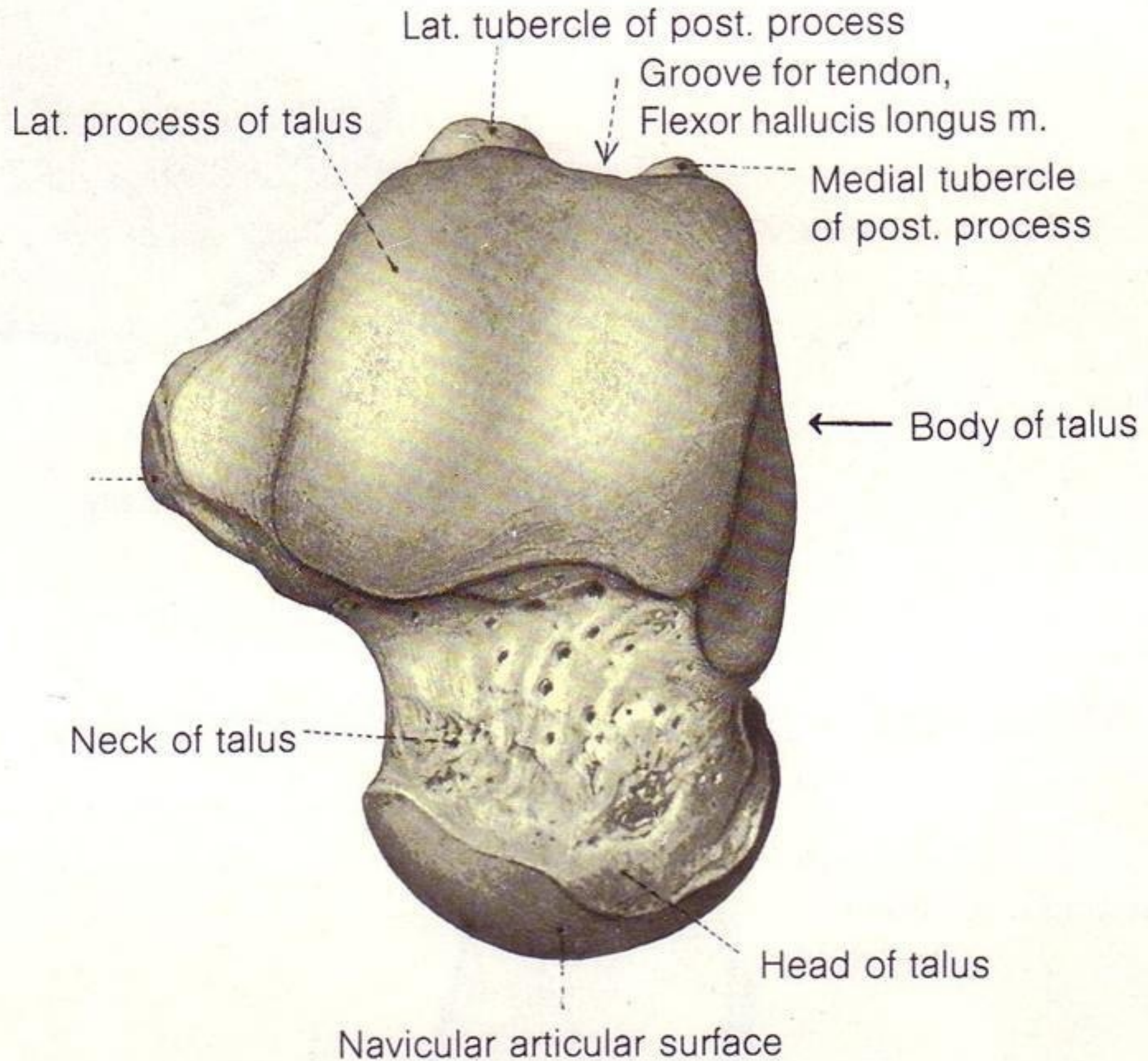
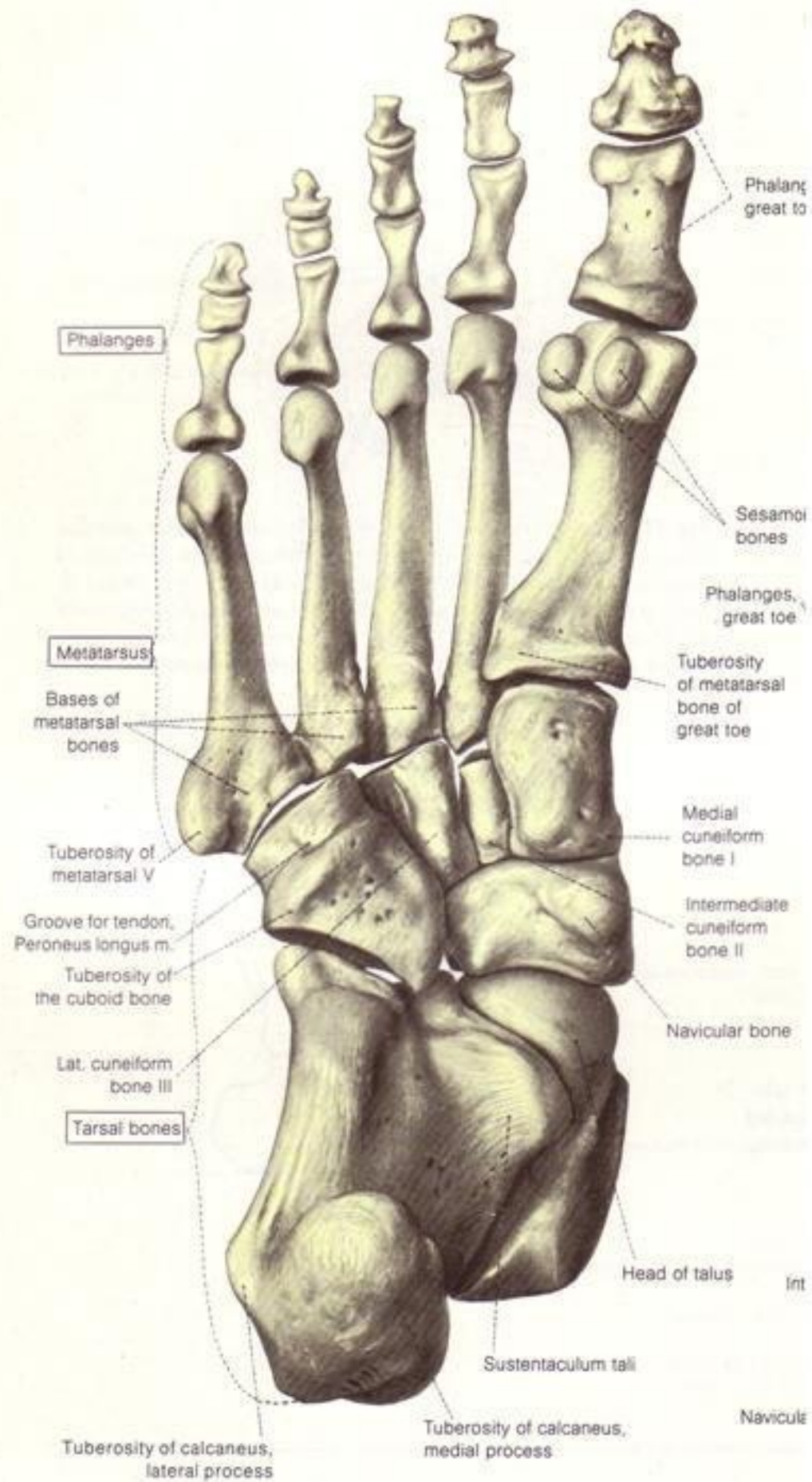


Fig. 524.









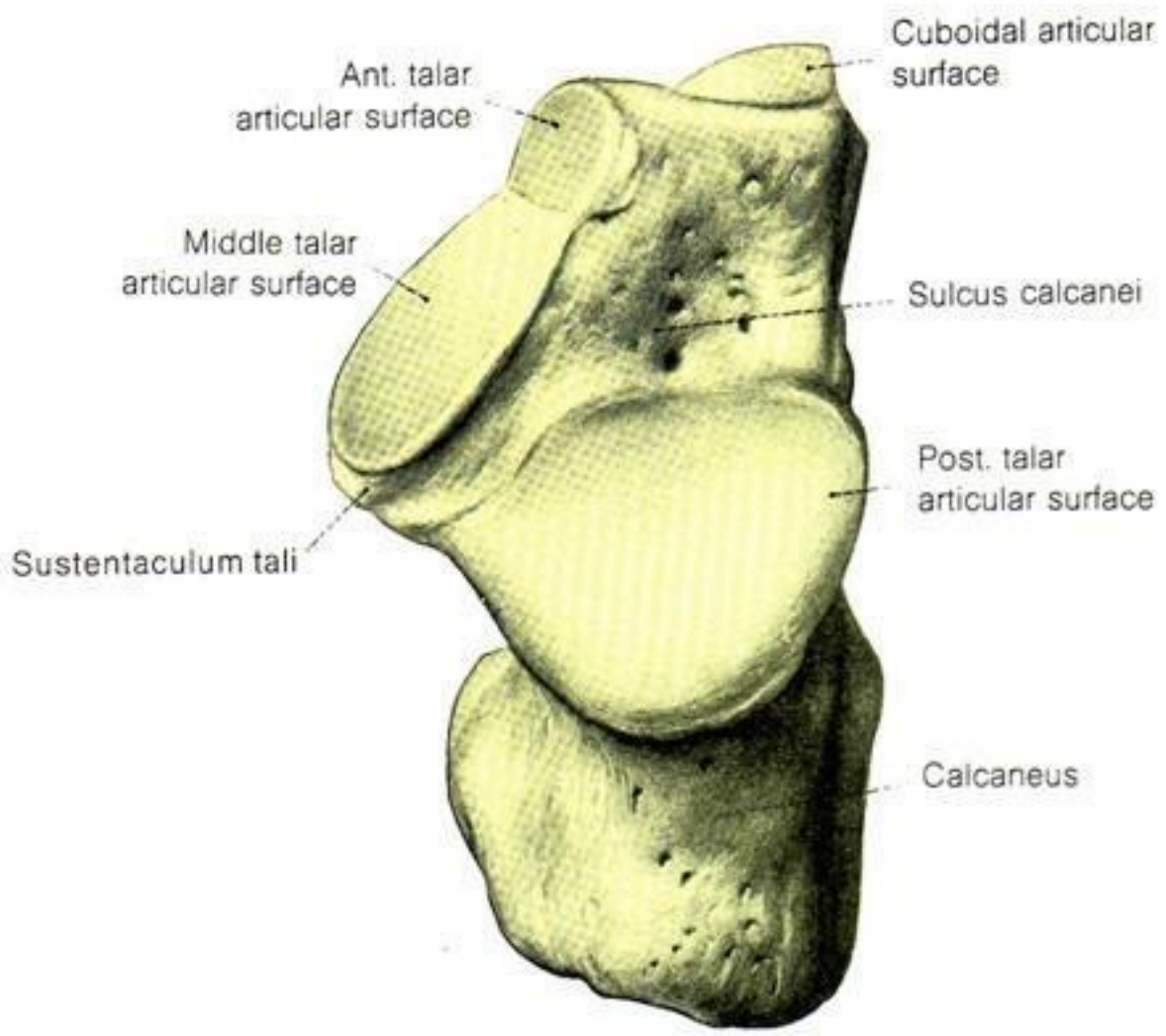


Fig. 527. Right calcaneus. Dorsal view.

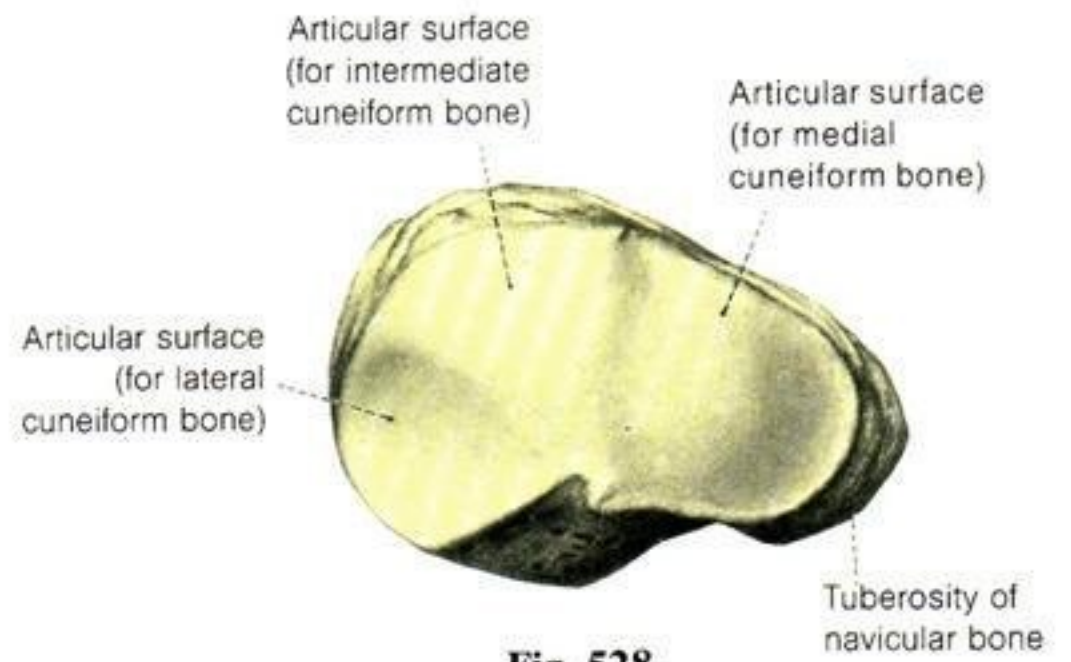
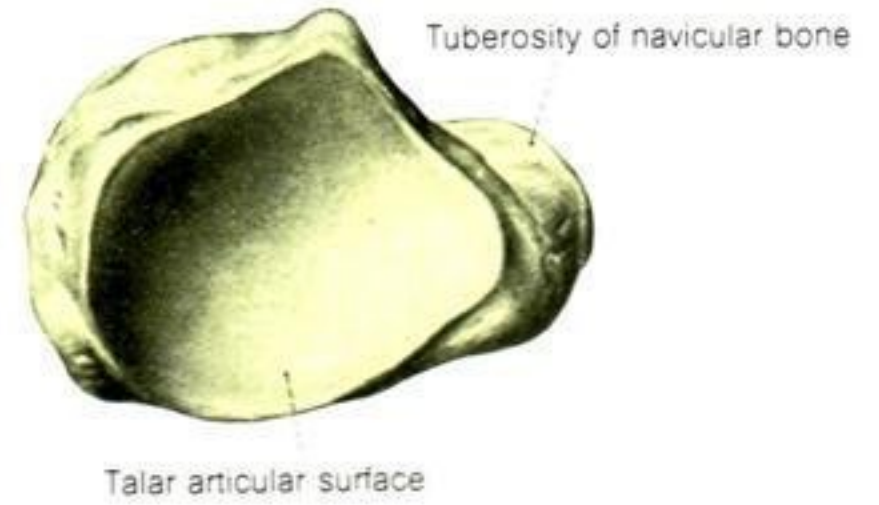


Fig. 528.



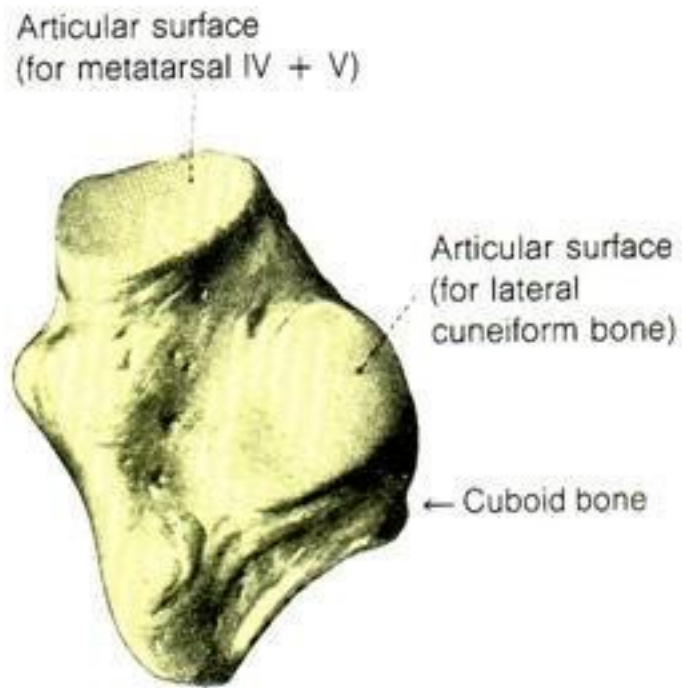


Fig. 530. Right cuboid. Medial view. (See also Fig. 521.)

Figs. 528 and 529. Right navicular bone.
Fig. 528: Distal view. Fig. 529: Proximal view.

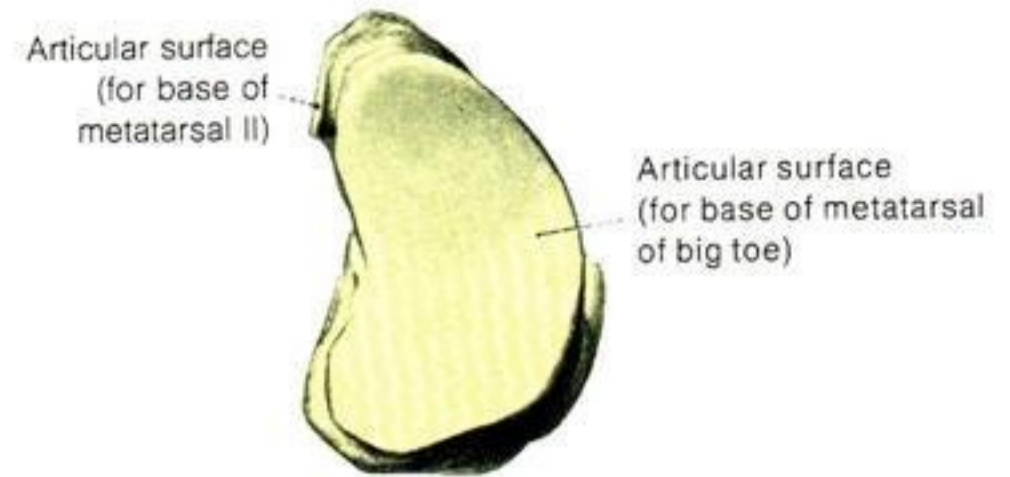
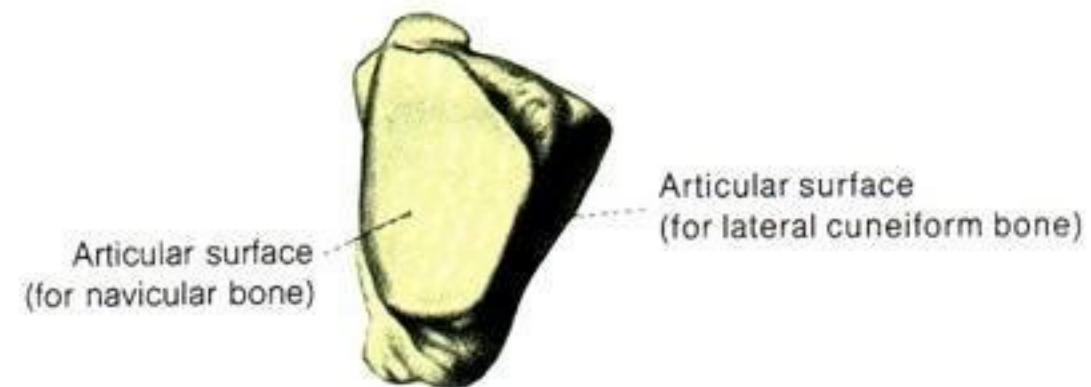
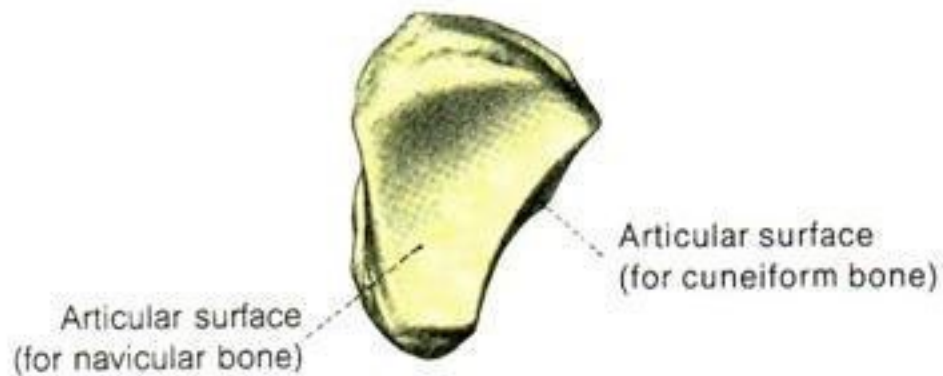
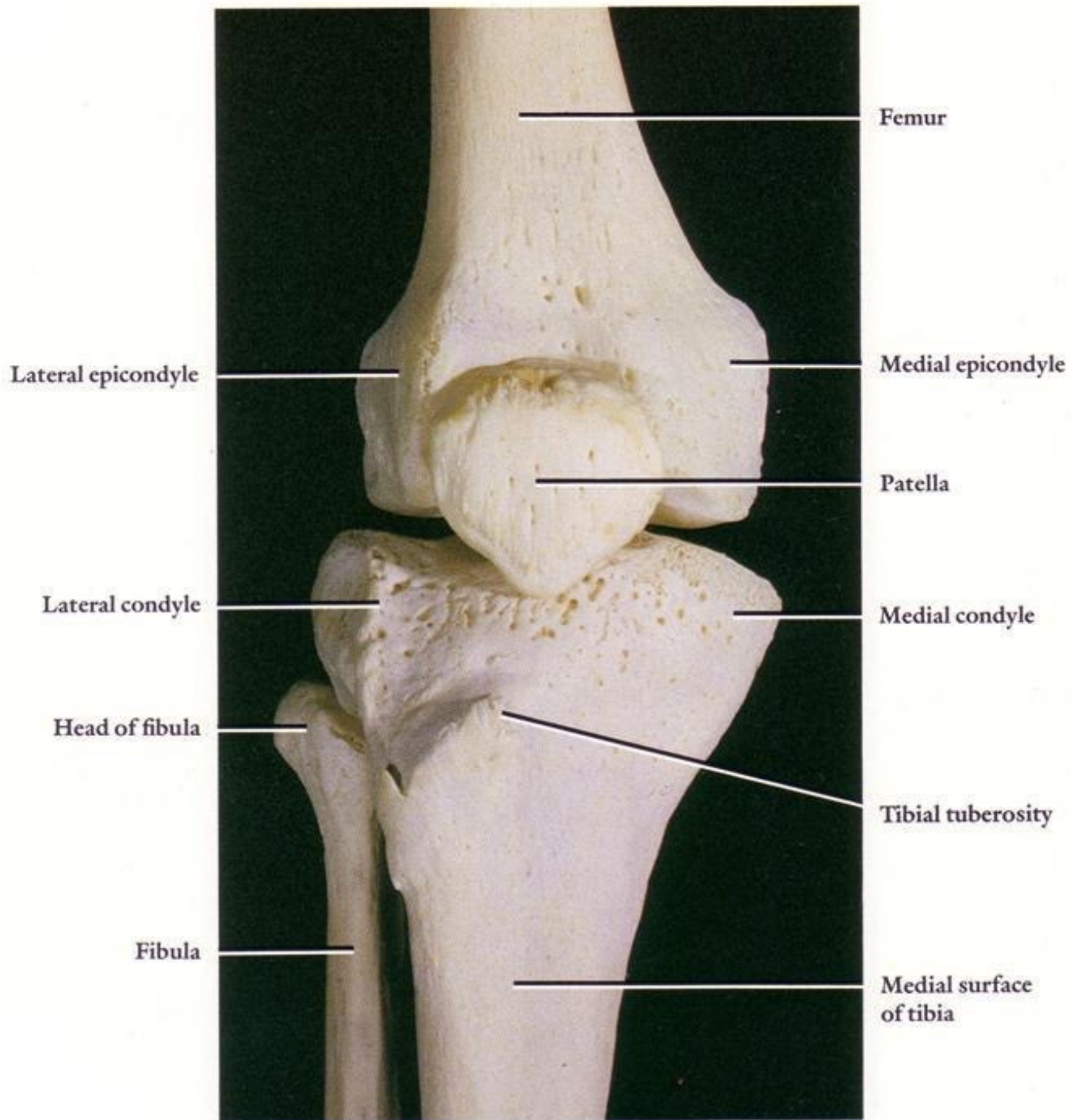
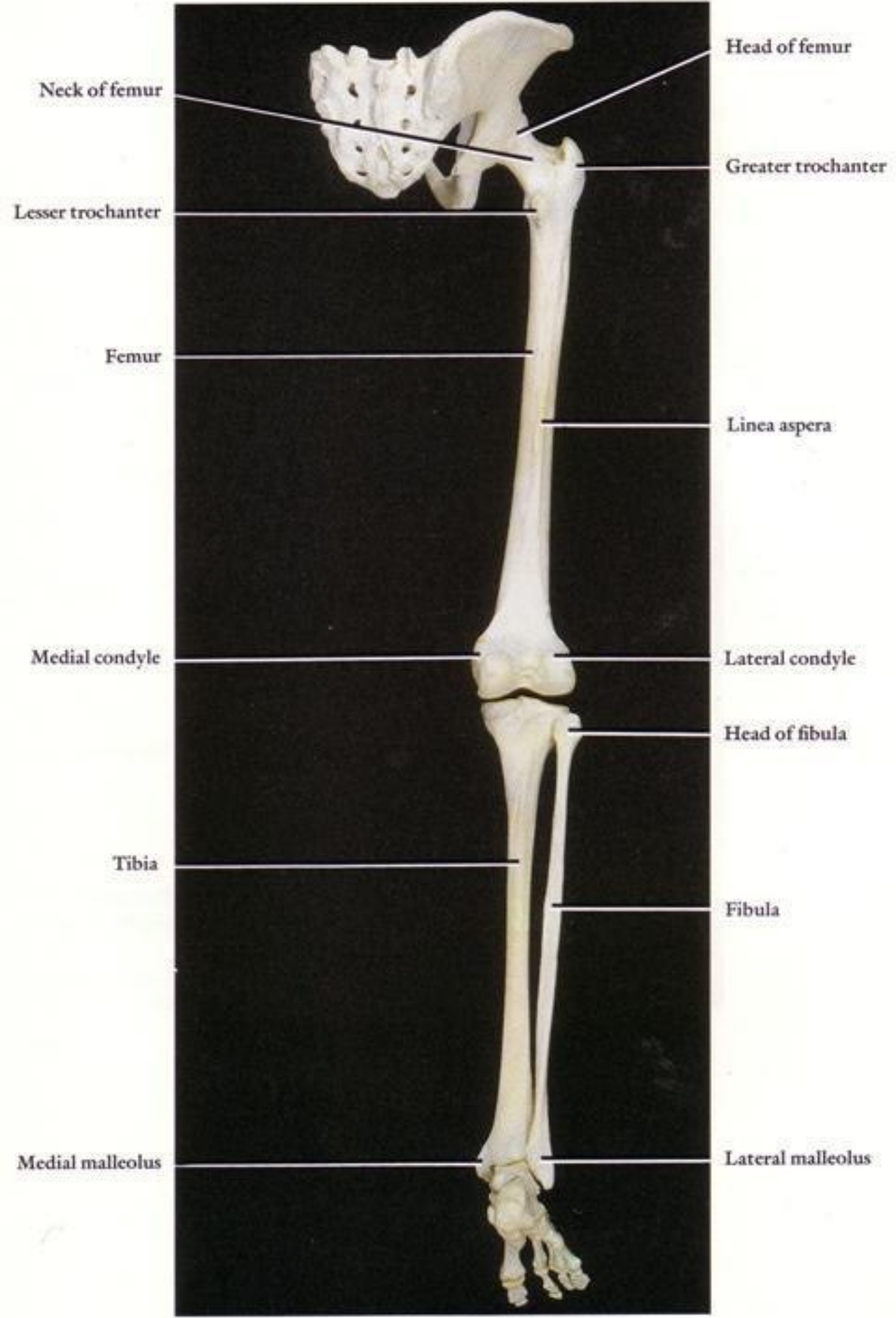
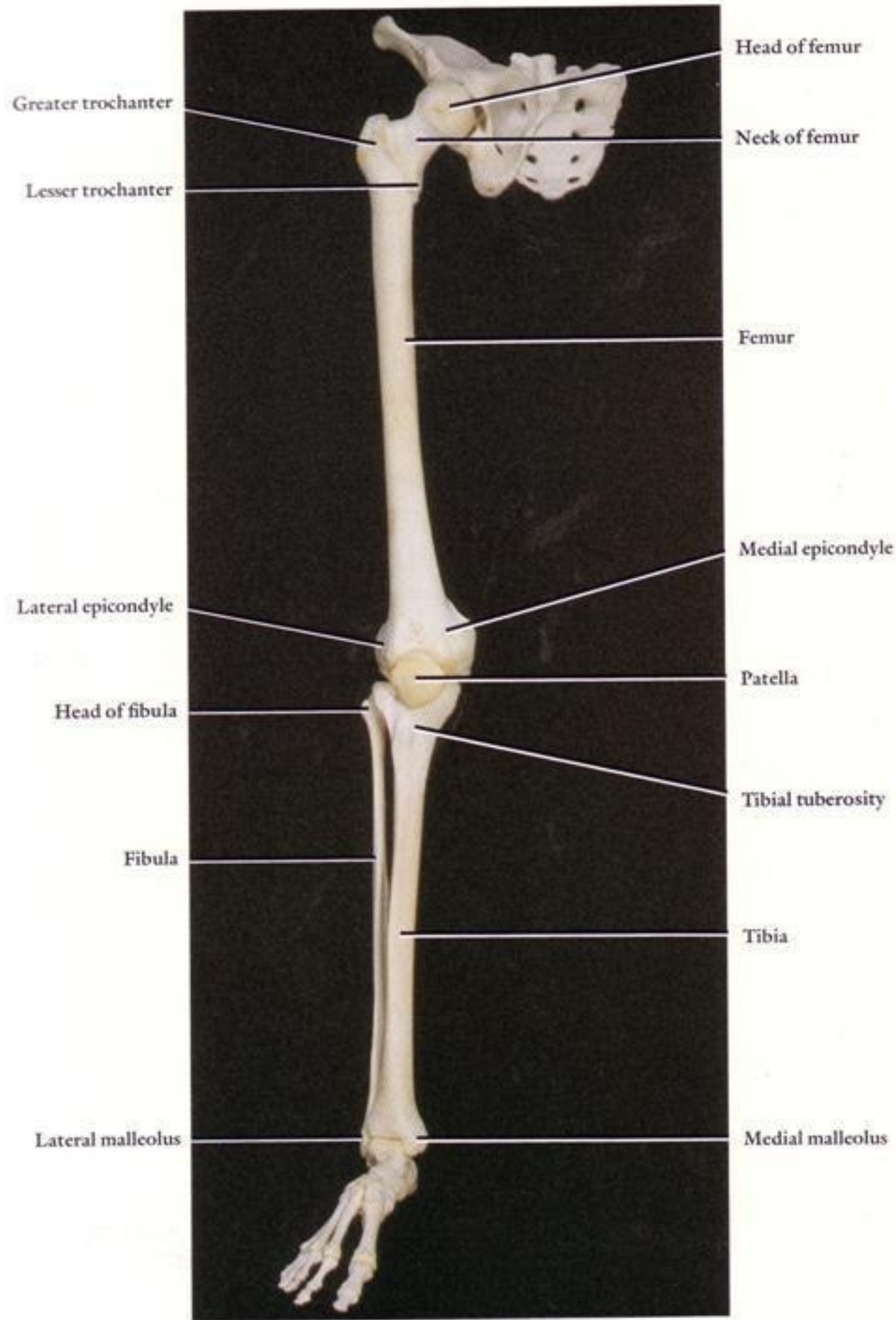


Fig. 531.









Popliteal surface
of femur

Adductor tubercle

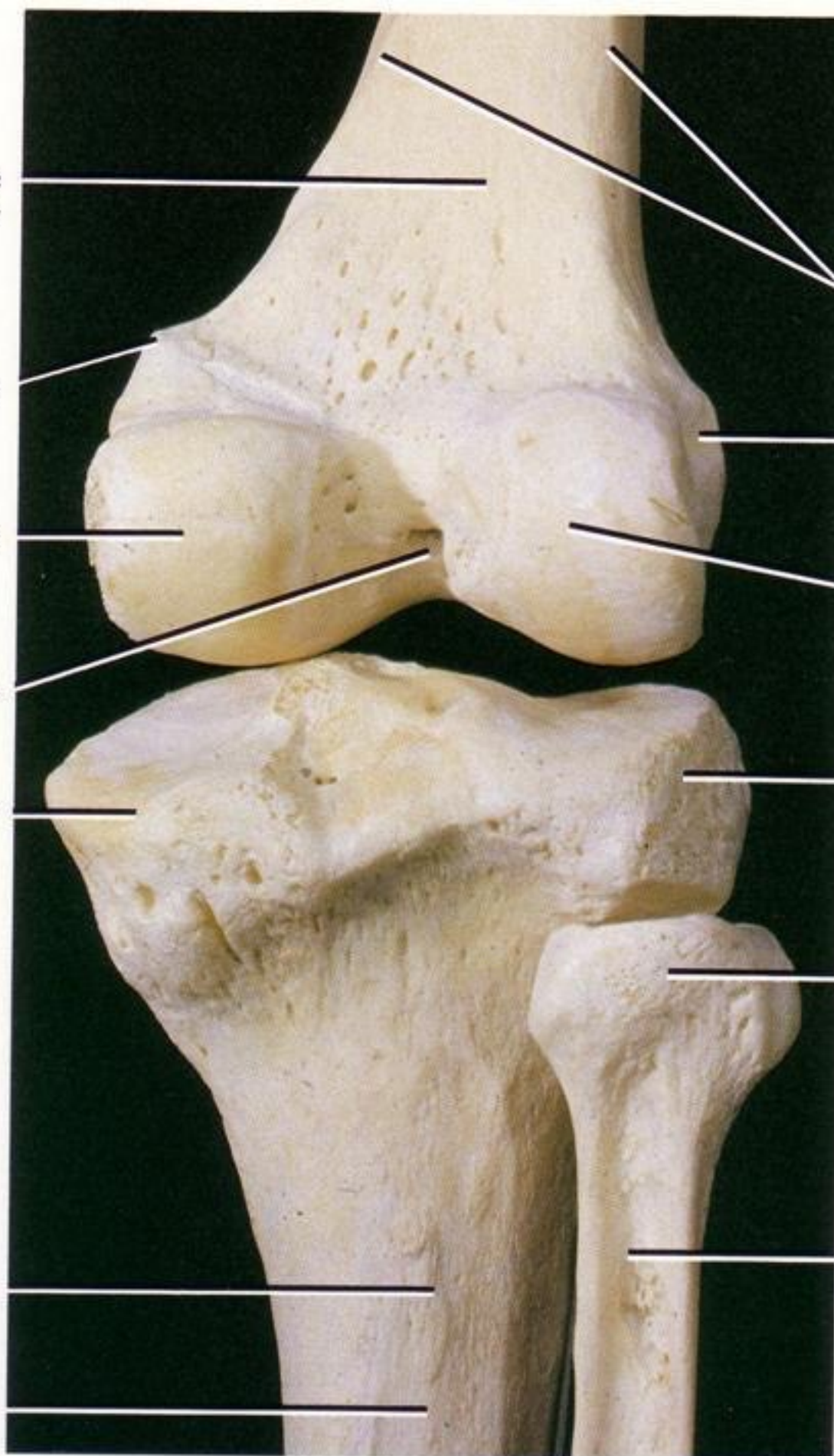
Medial condyle

Intercondylar fossa

Medial condyle

Line for
soleus muscle

Posterior surface
of tibia



Medial and lateral
supracondylar lines

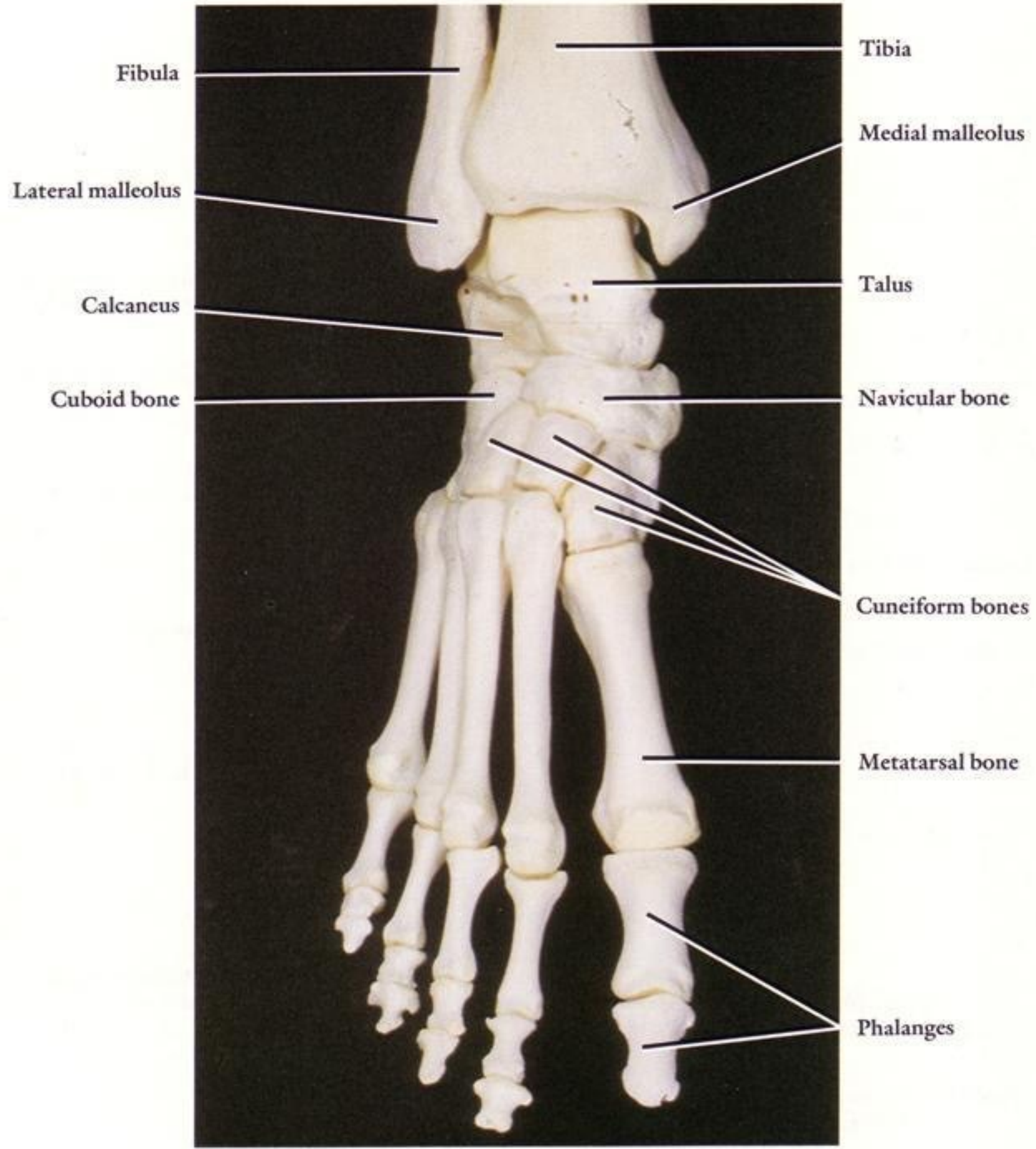
Lateral epicondyle

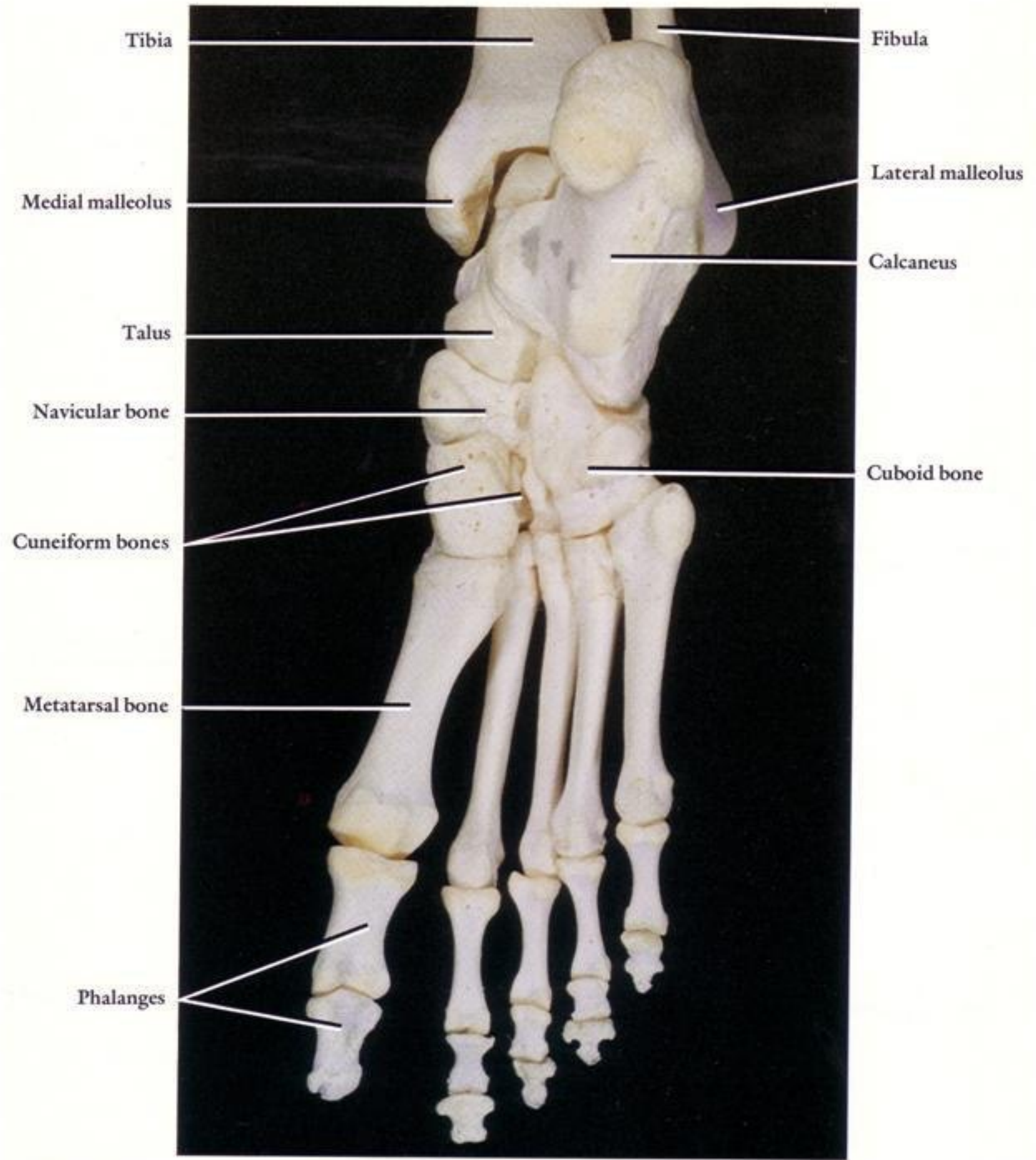
Lateral condyle

Lateral condyle

Head of fibula

Posterior surface
of fibula





Tibia

Fibula

Medial malleolus

Lateral malleolus

Talus

Calcaneus

Navicular bone

Cuboid bone

Cuneiform bones

Metatarsal bone

Phalanges